

AUA Handbook of Laparoscopic and Robotic Fundamentals



**Sean Collins, Daniel S. Lehman, Elspeth M. McDougall,
Ralph V. Clayman, and Jaime Landman**

Table of Contents

1. Introduction
2. Patient selection
 - a. Indication
 - b. contraindications
 - c. special considerations
3. Physiologic effects of pneumoperitoneum
 - a. Renal surgery transperitoneal
 - b. Renal surgery retroperitoneal
 - c. Hand-assisted laparoscopic nephrectomy
 - d. Prostatectomy
4. Getting Started
5. Patient positioning
 - a. Renal surgery transperitoneal
 - b. Renal surgery retroperitoneal
 - c. Hand-assisted laparoscopic nephrectomy
 - d. Prostatectomy
6. Strategic placement of surgical team and operating room (OR) equipment
7. Access
 - a. Primary access
 - b. Renal surgery transperitoneal trocar placement
 - c. Renal surgery retroperitoneal trocar placement
 - d. Secondary access
 - e. Retroperitoneal primary and secondary access
 - f. Hand-assisted laparoscopic nephrectomy trocar placement
 - g. Prostatectomy trocar placement
8. Instrumentation
 - a. Trocars
 - i. Cutting
 - ii. Dilating
 - iii. Radially dilating
 - b. Bipolar cautery
 - c. Monopolar cautery
 - d. Ultrasonic instrumentation
 - e. Vessel sealing devices
 - i. LigaSure
 - ii. Enseal
 - f. Staplers
 - g. Vascular clamps
 - h. Suture anchors
 - i. Titanium clips
 - j. Locking clips
 - q. Retractors
 - r. Hemostatic agents

- s. Hand Assisted devices
- 9. Technique for Transperitoneal Laparoscopic Nephrectomy
- 10. Complications of laparoscopic surgery

Chapter 1.

Introduction

The American Urology Association (AUA) has prepared this handbook for all those new to laparoscopy. Rather than being a detailed surgical atlas, this is a handbook designed to introduce the fundamental principles of laparoscopy including: indications and contraindications for laparoscopy, the physiologic effects of pneumoperitoneum, patient positioning; abdominal access and trocar placement; strategic placement of the operating room (OR) team and equipment, overview of laparoscopic instrumentation, and complications unique to laparoscopic surgery. Additionally, a detailed description of a laparoscopic nephrectomy is presented. The laparoscopic or hand-assisted laparoscopic approach has become the standard of care for most nephrectomies.¹ As such, it is imperative that every urologic surgeon be familiar with the procedure.

The details of complex reconstructive laparoscopic procedures are not included. It is hoped that the fundamentals presented in this handbook will serve as a sound foundation for those who wish to expand their skills to include more advanced procedures.

CHAPTER 2 **PATIENT SELECTION**

Indications

Laparoscopic or hand-assisted laparoscopic approaches have become the standard of care for radical nephrectomy when treating T1-T3a renal tumors and for dismembered pyeloplasty in adults.^{1,2,3,4} For benign adrenal tumors, including pheochromocytoma,⁷ laparoscopic adrenalectomy is the standard of care.^{5, 6 7 8 9} The laparoscopic approach is also a standard of care for nephroureterectomy¹⁰¹¹ and laparoscopy is the procedure of choice for the evaluation and treatment of a nonpalpable testis.^{12 13} Although rarely indicated, laparoscopy is also a reasonable approach in highly selected cases when ureterolithotomy and pyelolithotomy are being considered for very complex cases of urolithiasis.^{14 15} The safety and efficacy of the laparoscopic approach for these procedures has been demonstrated. The considerably decreased morbidity of a minimally invasive approach for these procedures makes laparoscopy a very appealing choice for patients.

In other areas, laparoscopy has become a widely utilized access technique. Both hand-assisted laparoscopic and “pure” laparoscopic living donor nephrectomy have been shown to procure a healthy graft while minimizing morbidity to the donor.^{16 17} Laparoscopic prostatectomy with or without robotic assistance has been shown to be equally effective in producing negative surgical margins (a surrogate endpoint of cancer control) as radical prostatectomy via an

open incision.¹⁸ Laparoscopic and robotic assisted radical prostatectomy are both associated with low morbidity and an expeditious convalescence. As such, both techniques are accepted as standards of care.¹⁸ During laparoscopic prostatectomy, the magnification of the laparoscope and the decreased bleeding associated with a pneumoperitoneum permit better visualization of the prostatic anatomy, however there is little published data on its improvement of continence and potency as compared to open surgery.¹⁸ If the follow-up data of laparoscopic and robotic prostatectomy confirm improved outcomes with less side effects, the robotic-assisted laparoscopic approach may become the standard of care for radical prostatectomy in the future.

Laparoscopic partial nephrectomy has been shown to have excellent results regarding positive surgical margins.^{1,19, 20} Unlike prostatectomy, with laparoscopic partial nephrectomy there is a marked advantage in terms of convalescence. As laparoscopic partial nephrectomy is an advanced reconstructive technique that is technically challenging and requires special training, it has largely become a standard treatment option for renal masses at tertiary care facilities with specially-trained urologists.

Similarly, laparoscopic radical cystectomy and urinary diversion are being performed only at select referral centers. At these larger centers, the indications for laparoscopic adrenal surgery are also expanding. Even large ($\geq 6\text{cm}$) and/or malignant adrenal tumors are being treated laparoscopically by Urologic surgeons with advanced laparoscopic skills.⁹ However, suspected adrenal malignancy remains a contraindication for laparoscopic adrenal surgery.

Urologic Surgeries for which the laparoscopic or

Hand-assisted approach is the standard of care

Adrenalectomy for benign pathology

Radical nephrectomy for T1-T3a renal cell carcinoma

Simple nephrectomy for benign disease*²¹

Nephroureterectomy for transitional cell carcinoma

Dismembered pyeloplasty in adults

Pelvic lymphadenectomy^{22 23}

*Excluding severe inflammatory conditions such as XGP

Urological surgeries for which the laparoscopic or

Hand-assisted approach is an accepted standard of care

Partial nephrectomy

Radical prostatectomy

Living donor nephrectomy

Urological surgeries for which the laparoscopic

Approach is limited to specialized centers

Radical cystectomy and urinary diversion

Adrenalectomy for adrenal cortical carcinoma

Adrenalectomy for ≥ 6 cm masses

Retroperitoneal lymph node dissection

Contraindications

The only absolute contraindications to laparoscopic surgery are those conditions that are contraindications to surgery by any approach, such as uncorrected coagulopathy, or severe uncompensated cardiopulmonary disease.¹

Special circumstances

COPD - Patients with severe chronic obstructive pulmonary disease (COPD) are at risk of developing hypercarbia during laparoscopy. During laparoscopy, CO₂ gas is used to expand and maintain body cavities, creating a pneumoperitoneum for working space. In healthy patients, the CO₂ gas is absorbed into the systemic circulation and quickly eliminated by the lungs. However, elimination of CO₂ by the lungs is limited in patients with COPD. As expired CO₂ levels are unreliable in the presence of COPD, arterial CO₂ levels should be checked every 1-2 hours during laparoscopic surgery in patients with pulmonary compromise. If hypercarbia develops, lowering the intra-abdominal pressure (IAP) from the standard insufflation pressure of 15mmHg to 12 or 10mmHg is usually helpful. If the decreased insufflation pressure does not adequately correct hypercarbia, an alternative is insufflation with helium gas. Helium insufflation may correct the metabolic derangement and may prevent conversion to an open procedure.¹¹⁰.

Pregnancy - Pregnancy is no longer considered a contraindication to laparoscopy. Initial concerns of placental ischemia in response to

pneumoperitoneum (PP) have not been supported by animal studies with intra-abdominal pressures (IAP) up to 10 mm Hg. However, at 20mm Hg, a pressure that is higher than standard accepted working pressure, significant cardiopulmonary alterations were seen in both the mother and fetus.²⁴ Recent case reports document uncomplicated nephrectomy, adrenalectomy, appendectomy, and cholecystectomy in pregnant women.^{25 26 27} In fact, before the third trimester, the laparoscopic approach has become the standard of care for performing appendectomy and cholecystectomy during pregnancy.²⁷ A retrospective review of 2182 laparoscopic and 1522 open, non-obstetric surgeries performed on pregnant women in Sweden found no increased risk of complications for the fetuses in the laparoscopic group compared to the open group.²⁸ The only complication related to laparoscopy was uterine insufflation with a Veress needle. In pregnant patients, it may be prudent to obtain access using an open technique in the upper abdomen above the uterine fundus and to keep IAP at 10 mm Hg or less.

Obesity - Obesity is no longer considered a contraindication to laparoscopy. A retrospective review of 189 patients who underwent laparoscopic radical nephrectomy, partial nephrectomy and simple nephrectomy evaluated outcomes for obese patients defined as having a body mass index (BMI) ≥ 30 kg/m² and lean patients having a BMI < 30 kg/m². The obese patients had slightly higher operative time, blood loss, and transfusions rates. However, there were no significant difference in conversion rates, analgesic requirements, hospital stay, time to oral intake, and major and minor complications in the obese patients

compared to the lean patients.²⁹ Other studies have demonstrated the safety of laparoscopic renal surgery in obese patients and that the benefit in terms postoperative morbidity is more pronounced in obese patients than in lean patients.^{30 31 32} As a result, laparoscopy has become the approach of choice for bariatric surgery.³³

Adhesions – Previous surgery with severe intra-abdominal adhesions were previously considered a contraindication to laparoscopic surgery. However, laparoscopy has been shown to be a safe method for lysis of intra-abdominal adhesions with significantly fewer wound complications and faster convalescence and return of bowel function than open lysis of adhesions.³⁴ A recent review of this topic suggested the following parameters to exclude patients from laparoscopic lysis of adhesions; massive abdominal distention preventing access, peritonitis, hemodynamic instability, severe co-morbid conditions – coagulopathy, cardiac disease, pulmonary disease and lack of comfort by the surgeon with the technique.³⁴ In an effort to minimize the risk of damage to adherent structures, primary access should be obtained away from previous incisions where there is the highest probability of underlying adhesions. If safe access cannot be reliably obtained with a closed (Veress needle) technique, then an open (Hasson trocar) technique should be used. See Chapter 4 for details of these two access methods.

CHAPTER 3

PHYSIOLOGIC EFFECTS OF PNEUMOPERITONEUM

Introduction

To develop working space for laparoscopic procedures, potential spaces are realized by expansion with CO₂ gas to create a pneumoperitoneum (PP). For transperitoneal procedures, the space between the visceral and parietal peritoneum is insufflated. CO₂ gas is used preferentially because it is colorless, odorless, non-flammable, and readily available. Additionally, CO₂ gas is quickly absorbed from body cavities and rapidly eliminated by the lungs in healthy patients.³⁵ The rapid absorption of CO₂ prevents prolonged distention of the abdomen postoperatively.

Fifteen mmHg is used as the standard insufflation pressure. There are multiple reasons for the use of a 15 mmHg threshold. Above all, it is a function of basic cardiovascular physiology. This is because the elevated IAP exerts its effects primarily on the cardiovascular system and secondarily on the pulmonary and renal systems. It is well known that the cardiopulmonary, renal and abdominal affects are minimal and still reversible at an insufflation pressure of less than or equal to 15mmHg.

Most animal studies have shown that an intra-abdominal pressures of 20 mmHg markedly impairs renal function, reducing GFR and RBF to 21% and 23% of their baseline values, respectively³⁶. There are similar studies that show adverse cardiac and pulmonary effects for prolonged intra-abdominal pressures of 20mmHg. These studies have been with pressure lasting over

three hours. Therefore, brief increases to a pressure of 20mm are tolerable. In fact, transiently raising the intra-abdominal pressure up to 20mmHg is a commonly applied maneuver for helping to control bleeding. As normal central venous pressure is between -1 to 5 cmH₂O, by briefly increasing the insufflation pressure to 20 mmHg, the surgeon can minimize venous bleeding and stop oozing. This 'tamponade effect' improves the exposure and allows the surgeon to work in a drier field. It's important to be mindful and reduce the insufflation pressure back to 15mmHg once hemostasis has been obtained.

Cardiovascular effects

The pressure exerted by continuous pneumoperitoneum is transmitted and distributed evenly to the patient's vasculature. This, in effect, increases peripheral arterial resistance. Similarly, central venous pressure increases, resulting in a decrease in the peripheral venous return. At the onset of IAP, there is an increase in venous return to the heart (increased preload), increased cardiac output, increased stroke volume and increased mean arterial pressure. As the PP continues, venous return decreases and arterial resistance increases, which leads to a modest decrease in stroke volume, with a compensatory increase in heart rate. The net effect of these physiologic alterations is that there is no change in cardiac output.¹¹⁰ Overall, these physiologic changes are not clinically significant unless the patient is hypovolemic or the intra-abdominal pressure (IAP) goes above 20 mm Hg.

Cardiac risks that are concerning during IAP are arrhythmias, which is secondary to hypercarbia and acidosis. Elevated CO₂ acts by stimulating the sympathetic response, releasing catecholamines, and causing vasoconstriction. This leads to an increased heart rate and blood pressure, ultimately leading to arrhythmias.

Pulmonary Effects

The intra-abdominal pressure (IAP) of the pneumoperitoneum (PP) is also transmitted to the thoracic cavity. Indeed, pulmonary effects of the PP are both mechanical and metabolic.³⁷ With respect to respiratory function, changes in pulmonary physiology are primarily mechanical; meaning that increases in intra-abdominal pressure and volume hinder diaphragmatic motion. The increased intra-abdominal pressure increases intra-thoracic pressure and decreases respiratory compliance, which leads to increases in peak and mean airway pressures and decreases vital capacity and compliance.³⁸ Pulmonary effects can also be metabolic, in that CO₂ absorption occurs across the peritoneum. As the CO₂ is transported to the lungs, it can lead to hypercarbia and acidosis. Hypercarbia, in healthy individuals can be corrected by ventilation and acidosis by the body's innate buffering system. However, Patients with chronic obstructive pulmonary disease (COPD) have difficulty tolerating the pneumoperitoneum and develop hypercarbia unless they are hyperventilated. Controlling respiratory rate and tidal volume is needed to maintain CO₂ arterial pressure below 50 mm Hg in

this patient population. As patients with COPD may not transfer CO₂ appropriately from the pulmonary vasculature to the alveoli, hypercarbia may not be evident by end-tidal CO₂ measurements alone. Therefore, in patients with COPD undergoing laparoscopy, frequent arterial blood gas measurements are necessary.¹¹⁰ If hypercarbia develops, lowering the intra-abdominal pressure (IAP) from the standard insufflation pressure of 15mmHg to 12 or 10mmHg is usually helpful. If the decreased insufflation pressure does not adequately correct hypercarbia, an alternative is insufflation with helium gas. Helium insufflation may correct the metabolic derangement and may prevent conversion to an open procedure.¹¹⁰ In the majority of operating rooms, Helium gas is not readily available. As such, the surgical team should anticipate the possible need for Helium insufflation and inform the operating room staff in advance. Indeed, working with the insufflator manufacturer may also be required as some insufflation devices may be damaged by the use of Helium gas. If hypercarbia persists despite decreasing insufflation pressure or conversion to Helium gas, the operation should be converted to an open procedure.

In addition to pneumoperitoneum, patient positioning can have a significant effect on pulmonary function during laparoscopic surgery. Prolonged application of the Trendelenburg position increases chest wall resistance and dead space and thereby decreases the alveolar-arterial diffusion of O₂. The effects of Trendelenburg are especially pronounced in obese patients.³⁹ One method of correcting this is by increasing the patient's

respiratory rate and tidal volume, which raises compliance associated with trendelenberg.³⁸ Minimizing the Trendelenberg position or application of a reverse Trendelenberg position are easy techniques for decreasing some of the effects of CO₂ insufflation.

Renal effects

Pneumoperitoneum causes a significant decrease in urine output. In general, the decreased urine output seen clinically during PP at levels near 12 to 15 mm Hg is transient and is not associated with permanent renal impairment. Once the PP is released, urine output returns almost immediately.⁴⁰ There are two potential factors that cause this transient oliguria; decreased renal blood flow and renal parenchyma compression. In an animal model, oliguria is associated with a corresponding decrease in renal vein flow, but does not appear to be associated with any permanent renal derangement nor any transient histological changes.⁴¹ Recent porcine studies have shown that a PP of 12mm Hg, decreases renal blood flow by only small amounts, compared to the significant decrease urine output. Therefore, the decrease in urine output seen during PP at commonly used pressures cannot be explained completely by decreased renal blood flow.⁴² Indeed, compressive effects on the renal parenchyma, as well as the renal vasculature and inferior vena cava combine to ultimately translate into an inhibited glomerular filtration rate, creatinine clearance, sodium excretion and urine output. This physiological event is the result of renal parenchymal

compression and venous insufficiency that is transient and reversible upon desufflation, and does not cause long-term renal sequelae. IPP does not cause decreased blood flow as much as can reverse Trendelenberg or patient dehydration⁴³.

Because the oliguria seen with PP is transient and almost immediately reversible, patients should not be over-hydrated in response to the physiologic oliguria of pneumoperitoneum. Pre-operative discussion with anesthesiologists unfamiliar with laparoscopy can prevent over hydration resulting from the anesthesia team attempting to increase the urine output.

Splanchnic effects

Decrease blood flow has been reported in other abdominal organs including the liver, pancreas, stomach, spleen, small intestine and the colon.⁴⁴ Delayed mesenteric thrombosis after PP has been observed, but this is not a common complication of laparoscopic surgery.⁴⁵

CHAPTER 4

GETTING STARTED

As, all laparoscopic cases require basic equipment, several companies are now offering fully integrated laparoscopic operating rooms, which provide an ideal layout for performing minimally invasive and conventional procedures. Karl Storz's OR1™ and Stryker's i-Suite® Operating Rooms are two examples of surgical suites designed to provide simpler work space by means of sterile touch control directly in the field. As device settings can be freely defined and activated, integration of existing systems including control of all functions via touch and speech control lead to shorter setup and changeover times. These OR's combine - optimal picture quality from various camera and monitor systems and other signal sources, control of the full range of functions of devices and peripheral systems made by other manufacturers, such as the OR table and room lighting, multimedia applications for audio and video communication (telemedicine) – all into one.

Monitors – Currently there are two types of monitors available. The larger and more “box like” monitors are known as cathode ray tube (CRT) monitors. While of high quality and very durable, CRT monitors will no longer be manufactured by medical technology companies. Recently, multiple manufacturers have introduced flat screen display panels. In most procedures, there is a master and a slave monitor system is used for most procedures. Usually, the master receives

the signal from the camera box directly, and the slave monitor receives its signal from the master. The usual screen diagonal size is 19 inches. Newer, high-resolution flat display panels are now being used with increasing frequency. Some of these newer monitors also have sterile touch function allowing the surgeon to command the entire laparoscopic video system via the flat monitor.

Laparoscopic optics - Telescopes or laparoscopes come in various sizes and with various visualization capabilities. Typically, one of six types of telescopes can be used. There is either a 5mm or a 10 mm laparoscope; size describing the maximum diameter of the instrument. Both 5mm and 10mm laparoscopes are constructed with either flat (0 degree lens) or with angled lenses that can provide additional optical versatility by giving the operative team the ability to look at the surgical field with an angle up to either 30 degrees or 45 degrees by rotating the laparoscope. With a 0 degree lens, the lens is flat and rotating the laparoscope does not alter the angle of vision. There is variability in surgeon preference for lenses, but having a 0 degree and 30 degree lens available for all cases is prudent. With contemporary technology, 5-mm lenses are useful but provide slightly less capacity for light transmission and may appear dark. The darkness of the 5-mm lens may be accentuated by blood in the operative field as it is known that blood absorbs light.

Light Source - A 300-watt xenon light source is usually used. The light is transmitted via flexible, fiber optic bundles connecting the light source to the

telescope. The surgeon, equipment manager and the nursing staff should always be aware that the light cords have a limited life span. When a significant decrease in light delivery is noted, the surgeon should verify that the majority of the fiber optics are intact and functional. If the field is dark at the beginning of a case, independently checking the laparoscope as well as the light cord will usually identify the problem so that it can be rectified. Additionally, care should be taken turn off the light cord when it is not plugged into the laparoscope. The light at the tip of the cord produces heat which can ignite a fire and cause harm to the patient and operating room staff. Great care should be taken to prevent this type of light cord injury.

Insufflator - The CO2 pump should be a high flow insufflation pump with both low flow and high flow settings. There are number of insufflators and tubings on the market made by different manufacturers. These insufflators have different specifications. Generally, they are capable of delivering a high gas flow insufflation of 24 L/min, which is limited by the trocar or needle to which it is attached. The insufflation tubing contains a filter that prevents bacterial and viral contamination from possible backflow of surgical smoke, protecting both equipment and operating room personnel. Although there is no clinical evidence, there is a belief that tumor seeding can occur via gas tubing. The tubing not only has a Virus Filtration Efficiency (VFE) of 99.999% for viruses to 0.02 microns but also have hydrophobic membranes, which provide complete fluid backflow protection.

Contemporary insufflators electronically monitor, maintain, and control the intra-abdominal pressure at the level chosen by the surgeon. A CO₂ gas filter should be used between the pump and the trocar. A filter is typically incorporated into the insufflation tubing. Studies suggest that the use of warmed CO₂ insufflation has a significant impact on time spent cleaning the laparoscope, time spent changing warm saline and time spent using anti-fog.⁴⁶ Some insufflators are now equipped with CO₂ tubing warmer; thus the delivered CO₂ is warm (body temperature) which will theoretically decrease operative time.

Self-retaining retractor – There are a number of commercially available retraction systems that incorporate a locking retracting arm and different types of retractors. Typically, a self-retaining retractor is secured to the table on the opposite side from the surgeon and assistant. A self-retaining retractor system is a valuable tool in optimizing the surgeon's performance during laparoscopy. Using a locking arm and a retractor allows the surgeon to use both instruments for dissection rather than using one instrument for retraction and the second instrument as a solitary working device. "Two handed" surgery increase efficiency and safety.

CHAPTER 5

PATIENT POSITIONING

Renal Surgery – Transperitoneal Approach

For transperitoneal renal surgery, the patient is typically positioned in a 70 degree or 90 degree (full) flank position depending on surgeon preference. Anesthesia is induced, and all lines and monitors are placed before the patient is positioned. A nasogastric or orogastric tube and Foley catheter should be placed before the patient is positioned to decompress the stomach and bladder respectively. Careful padding of all pressure points is critical to minimize the risk of pressure induced neuromuscular injuries. Special attention should be taken for padding of pressure points including the ankle, knee, and hip. An axillary roll is placed to minimize the risk of brachial plexus injury.

The patient is then moved such that the table break is at the level of the anterior superior iliac spine. Using the draw sheet, the patient is then rolled onto his/her flank with the operative side up. The patient should only be moved after the anesthesia personnel have secured the endotracheal tube; otherwise there is the risk of accidental extubation. The patient's ventral surface should be on the edge of the table to allow the surgeon to drop his instruments when gaining access to the most lateral aspects of the surgical field. A beanbag is typically not necessary and may increase the risk of developing rhabdomyolysis. The lower leg is flexed at the knee and hip, and the upper leg remains extended. Pillows support the upper leg so that upper thigh is parallel with the floor and the hip is

not adducted. After being placed in the desired flank position, the table is “broken” to optimize the surgeon’s working space. Over-flexing the table should be avoided especially in very lean patients as this may limit the expansion of the abdominal wall and thereby limit the working space during the procedure. On the ipsilateral side, the patient is carefully anchored with tape and/or straps. The areas where tape or straps are applied should also be carefully padded. While the patient should be anchored very securely, care should be taken not to anchor the patient tightly around the thorax as over compression of this area can dramatically increase inspiratory pressures.

After the patient has been positioned and secured with tape the anesthesia team should be asked to check inspiratory pressures to ensure that the inspiratory pressures are not elevated after the chest wall has been secured. If inspiratory pressures are elevated, the tape should be loosened. A single arm board is utilized on the side of the table to which the patient is facing. Foam pads are placed above and below the lower arm. Pillows are placed below the upper arm, which is gently flexed at the elbow with the shoulder slightly abducted. The palm should be facing down. The patient’s upper arm should appear in a natural, fetal position. All venous and arterial lines in the upper extremities should be checked by the anesthesia personnel before the upper arms are secured to the arm boards gently with tape. Care should be taken to remove all lines and cords from under the patient, as these lines may cause pressure necrosis from the patient’s weight and/or body habitus.

The abdomen, flank and lower chest are prepped in a sterile fashion. The surgical field should be draped with the following boundaries: superiorly – the mid-chest; inferiorly – pubic symphysis; laterally – posterior axillary line; medially – operating room table below the umbilicus which exposes the midline.

Renal surgery – Retroperitoneal Approach

With retroperitoneal renal surgery, as with transperitoneal surgery, the patient is placed in the full flank position, with the affected side elevated. However, for retroperitoneal access the patient is placed in the center of the bed rather than having the umbilicus at the edge of the surgical table. The table should be flexed maximally, with the patient placed so that the iliac crest is just caudal to the table break. Proper positioning increases the working space by allowing the retroperitoneum to open. All other steps of retroperitoneal positioning are the same as described for transperitoneal laparoscopic access.

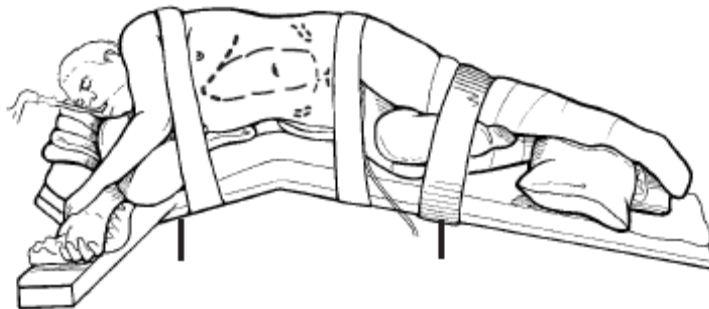


Figure 1 Positioning for left retroperitoneal laparoscopic nephrectomy.

For transperitoneal approaches, we prefer a similar position but with the umbilicus positioned over the edge of the table⁴⁷

Hand-assisted laparoscopic renal surgery

The patient position is the same as for transperitoneal renal surgery. Most surgeons apply a modified flank position at 70° or a full flank 90° position. As with “pure” laparoscopic transperitoneal cases, it is important that the patient be positioned at the edge of the surgical table to prevent the instruments and camera from striking the surgical table, which may significantly limit movement during the case.

Prostatectomy

The positioning for both pure laparoscopic and robotic assisted prostatectomy is similar. After the induction of anesthesia and appropriate vascular access is obtained, a nasogastric or an orogastric tube is placed. The Foley catheter is placed in sterile fashion after prepping and draping are complete.

For robotic-assisted laparoscopic prostatectomy, the patient must be placed in a modified lithotomy position to allow the robot access to the surgical table. The head is placed in extreme Trendelenberg so that the intra-abdominal contents can be kept out of the pelvis. (Figure 2) For a “pure” laparoscopic prostatectomy, either the lithotomy or the supine positions are both acceptable. If the supine position is chosen, the thighs and legs should be slightly abducted to allow access to the perineum.

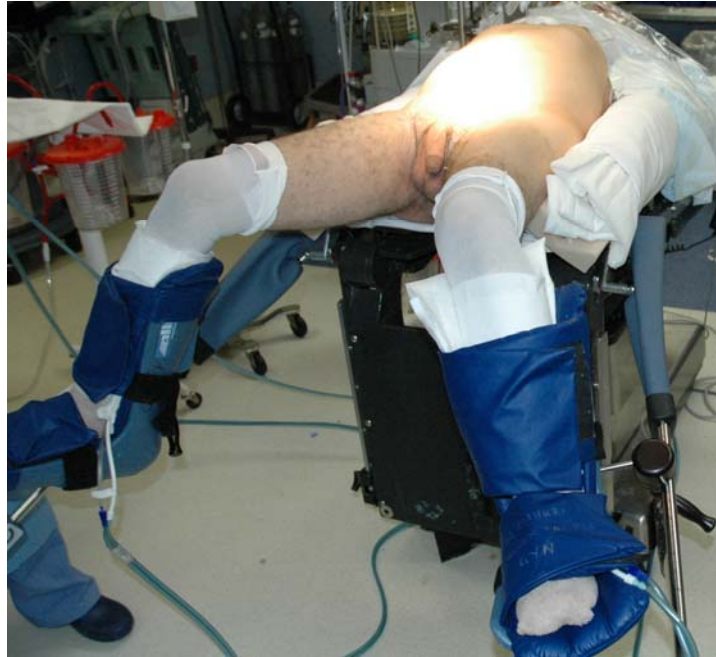

Figure 2. Robotic Prostatectomy positioning

When utilizing lithotomy position, the foot of the bed is dropped and the buttocks are brought to the end of the table. The legs are placed in the low lithotomy position with the ankle, knee, hip, and contralateral shoulder in line. The weight of the leg should rest on the heel rather than the back of the knee or the lateral surface of the lower leg, because this may cause popliteal artery occlusion or peroneal nerve injury, respectively.⁴⁸

The arms are placed on foam pads and tucked at the patient's sides. The palms should be supported and pronated. (Figure 2) Typically, the use of an arm board should be avoided. The arm board increases the distance of the surgeon from the surgical field, thereby increasing the length he or she must reach across the patient and may further complicate intracorporeal suturing. For obese

patients, it may be necessary to place an arm board on the side of the table to support the arms.

The abdomen, genitalia, perineum, and thighs are prepped in a sterile fashion. The drapes should be placed with the following boundaries: superiorly – epigastric area; laterally – patient’s arms; inferiorly – anterior margin of the anus. The perineum must be exposed to allow a “perineal push” to advance the urethral stump into the surgical field during the vesicourethral anastomosis if necessary.

CHAPTER 6

STRATEGIC PLACEMENT OF OPERATIVE EQUIPMENT AND THE OPERATIVE TEAM

For transperitoneal renal laparoscopic cases, the surgeon and assistant both stand on the ventral aspect of the patient. Conversely, with retroperitoneal access, both the surgeon and the assistant stand on the dorsal aspect of the patient. The laparoscopic “tower” (shelves containing the insufflator, camera box, and light source), should be in the surgeon’s line of view. In this manner, the surgeon can rapidly assess any equipment problems (eg. loss of insufflation pressure) for expeditious resolution. Most importantly, the laparoscopic image (flat panel or CRT monitor) should be directly in the surgeon’s line of vision at a comfortable distance with an unobstructed view. Placing the monitor just below eye level of the surgeon is most ergonomic and minimizes neck strain.^{Error!}

Bookmark not defined. The monitor should be placed at a slight angle toward the surgeon, like reading a book. In new dedicated laparoscopic/endoscopic suites, the “tower” and the monitors are usually placed on booms originating from the ceiling. Thoughtful positioning of the booms will optimize the surgeon’s view of the working monitor and the “tower” components.

During any laparoscopic procedure, it is imperative that the surgeon remain in a comfortable operating position to minimize muscle fatigue and optimize surgical performance. One of the first considerations is table height. Most operating room tables will not lower adequately to provide the surgeon with a comfortable operating position. Operating with the table too high will rapidly

fatigue the muscles of the arms and shoulders and will decrease surgical performance and may lead to surgeon injury. To optimize table position, application of standing stools will often result in optimal surgeon height and position. To create a large and stable working space for the surgeons, we have found it useful to connect six interlocking step stools such that both the surgeon and assistant can comfortably share the space. Proper table height keeps the surgeon's arms and elbows at his/her side, which makes operating more comfortable. This is especially true for intracorporeal suturing where maximum range of motion is imperative. (Figure 3)

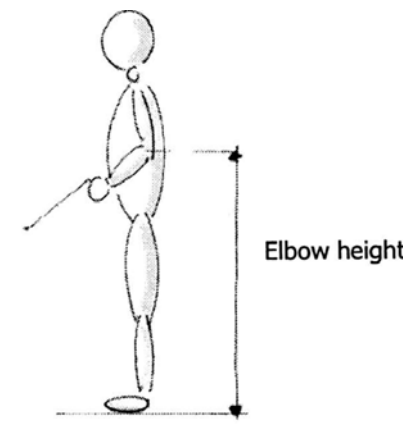


Figure 3a. Optimal posture of surgeon during laparoscopy⁴⁹

As the camera trocar site is usually positioned more medial than the working trocars, the camera must be angled up to view the operative field. In this position, the camera driver must hold the laparoscope and camera rather low. As such, we have found that allowing the camera driver to sit on a stool optimizes comfort and performance.

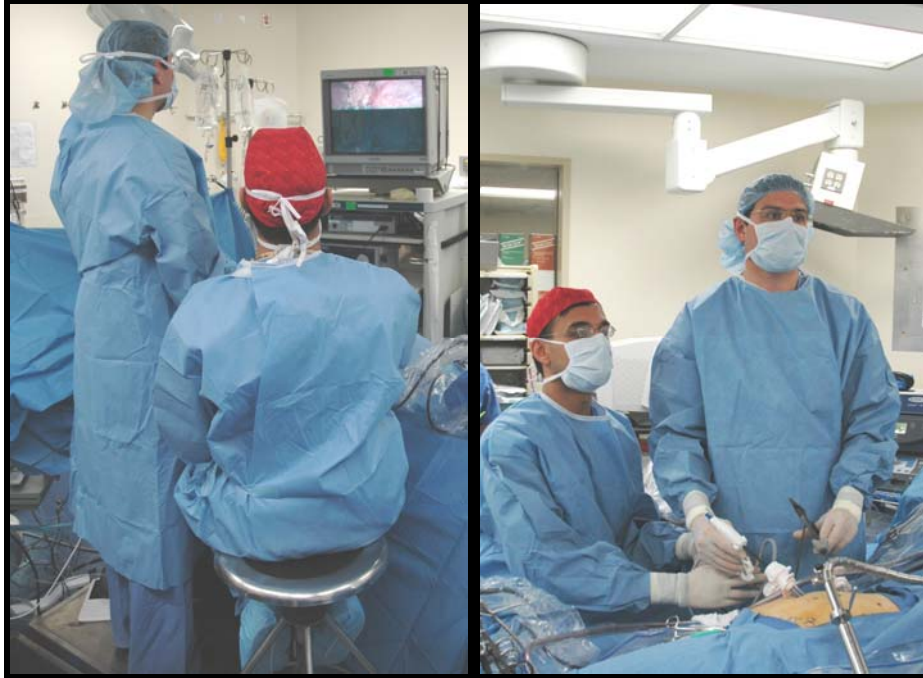

Fig. 3b Positioning of Primary Surgeon and Cameraperson; Note the comfortable arm positioning of both surgeons

Foot pedals are placed adjacent to the surgeon's dominant foot. The surgical scrub technician should be positioned at the foot of the bed opposite the surgeon. Ideally, if a second monitor is available, the surgical scrub technician should be able to observe the procedure with an appropriately positioned monitor to optimize his/her ability to assist efficiently by anticipating the surgeon's needs.

As laparoscopy is dependent on many tethered instruments (cords and tubing), organizing the cords can help minimize tangling of the instrumentation that can result in inefficiency. There is no strict pattern for running of cords and tubing. However, several basic concepts should be considered. First, to minimize tangling, the surgeon should keep only enough cord length for each instrument without excess. The surgeon should coordinate with the surgical team, and may need to reorganize the position of devices, to assure that each

instrument on the field has just enough cord length without any excess. Taking time to keep and maintain the cords in order will save time through out the case. The suction-irrigation tubing, bipolar cautery cord, surgical energy device cords such as the harmonic scalpel cord or LigaSure cord, and bovie cord should run off the head of the bed away from the surgeon. If a laparoscopic ultrasound is used, its cord should be run off the foot of the bed.

For pelvic laparoscopic procedures, such as radical prostatectomy, the surgeon typically stands on the patient's left side and the assistant stands on the patient's right side. A single monitor is placed between the patient's legs. All cords and the suction-irrigation tubing should be run off the head of the bed. A second monitor can be placed, where it is most comfortable for the surgeon during more complex tasks such as intracorporeal knot tying.

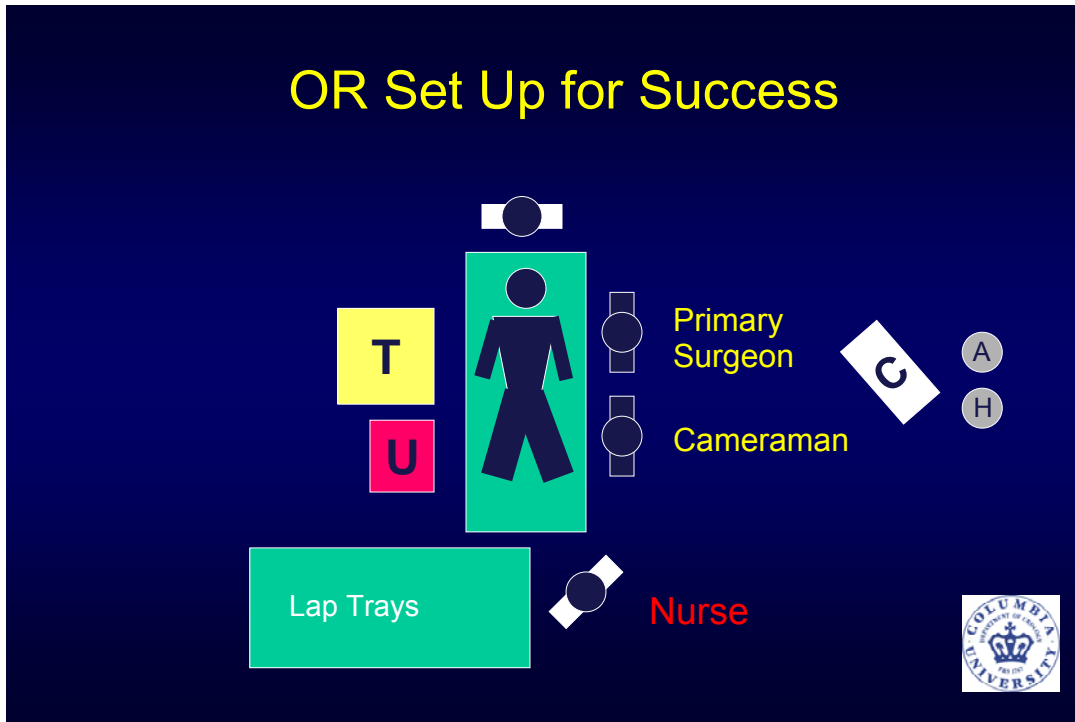


Figure 4. Positioning and room set up for Right-sided transperitoneal surgery or Left-sided retroperitoneal surgery (T=laparoscopic tower, U=laparoscopic ultrasound device)

Note in figure 4 that the surgeon and the cameraperson both have an unobstructed view of the laparoscopic image as well as the laparoscopic ultrasound. Keeping all optical cues in the line of vision will minimize the risk of injury which can occur when the surgeon or assistant move to visualize target structures.

CHAPTER 7

ACCESS

PRIMARY ACCESS

Veress needle technique

A Veress needle is a needle that contains a spring-loaded inner sheath. This sheath retracts as the needle is advanced through tissue exposing the needle tip. Once the needle enters the peritoneal cavity, and the majority of the resistance on the needle is released, the inner sheath springs forward. The inner sheath covers the needle tip and protects the intra-abdominal organs from being injured by the sharp end of the needle. To ensure that the Veress needle is properly placed within the peritoneal cavity, a regimented series of maneuvers is performed. The following sequence should be committed to memory and should be part of the routine whenever the Veress needle technique is used:

1. The Veress needle should be examined to ensure that the inner sheath retracts and that it flushes easily. Reusable Veress needles and even some new disposable needles will occasionally have resistance of the spring loaded inner sheath. If the sheath does not deploy properly, the needle may cause injury to body structures.

2. Two “clicks” should be felt / heard as the needle passes through the fascia and parietal peritoneum, respectively. Needle deployment is usually easy, but can be a challenge in very thin and obese patients.

3. Aspirate the needle. It should aspirate easily.

If blood, bowel contents, or fluid are aspirated, or if the needle will not aspirate, the needle should NOT be removed so as to help identify the site of injury. Of note, aspiration of bowel contents is subtle with very small particles in the syringe. As such, the aspirated fluid should be carefully inspected. If the needle is placed in a vessel or viscus, the urge to pull the needle out should be suppressed, the needle should be left in place, and an alternative access site should be obtained (either by Veress or open technique). After access has been gained, the site of original Veress needle injury should be immediately inspected to determine the nature and severity of the injury.

4. Irrigate 1-2 ml of saline into the needle.

5. Aspirate the needle again. It should aspirate easily. *Repeat as per above.*

6. Gently advance the needle 1/2cm. No resistance should be felt.

7. Remove the syringe from the needle. Fluid within the needle should drop rapidly into the abdominal cavity. This “drop test” confirms the position of the distal tip of the Veress needle in a low-pressure space.

8. Connect the needle to high flow CO₂ insufflation. There is no need to begin at low flow, because the size of the Veress needle limits flow to 1.5 to 2L/min. The opening pressure (initial pressure) should be <10 mm Hg (usually in the range of 5-7mmHg). *If the opening pressure is greater than this the needle should be withdrawn slightly. If the pressure decreases to <10 mm Hg, continue insufflating. This indicates that the needle tip was against an intra-abdominal*

structure such as the intestine or omentum. If the pressure remains ≥ 10 mm Hg, the needle is not properly placed. It should be removed and the Veress needle deployment algorithm repeated. If the needle has been properly deployed, the usual adult abdominal cavity will insufflate with approximately 3 to 5 L of CO₂ gas. During the insufflation process, the surgeon should observe that all four quadrants of the abdomen insufflate evenly (no one portion of the space should insufflate preferentially).

9. Once the intra-abdominal pressure reaches 15mm Hg, withdraw the Veress needle.

10. Insert the primary trocar. This may be done with a traditional or optical trocar. Bladed or cutting trocars should not be used at any time (See Chapter 6 Instrumentation for a discussion of trocar types).

11. Inspect the abdomen with the laparoscope. The distal tip of the trocar should be within the peritoneal cavity. *The area immediately under the primary trocar deployment site is the first place to be inspected for possible Veress needle or trocar injury. There should be no evidence of trauma such as blood, gastric fluid or urine in the peritoneal cavity. If any of these are found, the location and nature of the injury must be determined and the injury should be treated.*

12. Once it is confirmed that the trocar is properly placed, connect the insufflator to the trocar. Standard insufflation pressure is between 12 and 15 mmHg.

Deploying the Veress needle with this algorithm is safe and effective. A retrospective analysis evaluated 2126 consecutive cases performed with the Veress needle technique for primary access. In this study, there were no vascular complications related to the primary access. Two bowel injuries documented in the series were related to cautery, and not to the access technique.⁵⁰ In a review by Bonjer and colleagues on 489,335 closed patients and on 12, 444 open patients, the rates of visceral and vascular injury were respectively 0.48 % and 0.075% after closed laparoscopy, and 0.048% and 0.0% after open laparoscopy. Mortality rates after closed and open laparoscopy were 0.003% and 0%, respectively.⁵¹ With the Veress needle technique, the only minor complications were with subcutaneous emphysema.⁵² The existing body of literature does not show any advantage of either the open (Hasson) technique versus the Veress needle technique.

Hasson technique

The open or Hasson technique may also be used to access the abdomen.^{53 54} In this technique a small 12mm open peritonotomy is created. If a Hasson trocar is used, sutures are placed into the fascia and secured to the side arms of the trocar to hold it in place. The same sutures can be used for fascial closure at the end of the case.

Alternatively, a balloon trocar can be used (U.S. Surgical Corp / Tyco, Norwalk, CT). This device has a retention balloon which lies under the fascia and

is filled with 15-20 cc of room air. A moveable foam pad slides down to the skin and is secured in place with an incorporated clasp to prevent leakage of air.

The Hasson technique is indicated for children, very thin patients, pregnant women, patients with previous abdominal incisions who are likely to have extensive adhesions, and in patients with distorted anatomy where the spine and great vessels are near the desired primary access site.⁵⁵

Direct trocar insertion technique

Optical trocars have a translucent dilating tip and accommodate a camera so that the device can be advanced under vision. Direct insertion of an optical trocar without prior creation of pneumoperitoneum has been reported. This technique is discouraged because it is associated with a significant (2.1%) risk of bowel injury.⁵⁶ A survey of laparoscopic complications demonstrated significantly higher rates of access-related complications with direct insertion of an optical trocar compared to the open (Hasson) technique and the traditional technique (Veress needle pneumoperitoneum followed by primary trocar placement): 0.27% (3 of 1,009 cases); 0.18% (20 of 10,664 cases); and 0.09% (1 of 1,013 cases). ($p < 0.0001$)⁵⁷

SECONDARY ACCESS

Overview of Trocar Placement:

Proper trocar placement is essential to successful laparoscopic surgery. A few general principles are worth considering at the beginning of every case.

Multiple templates exist for each different Urologic laparoscopic procedure. There are, however, general guidelines that make any configuration more useful. Surgeon comfort is essential, as comfort will minimize fatigue and optimize surgical performance. Studies have shown that each individual surgeon should have an ideal table height. The table needs to be low enough such that the instrument handles are positioned with their elbows kept close to the body. Optimal table height corresponds to an approximate table height of 64 to 77 cm above floor level.⁵⁸ Surgeons can minimize additional forearm and shoulder muscle fatigue by maintaining instrument horizontal angulation at $<45^\circ$ and vertical angulation at $<15^\circ$ during laparoscopic surgery.⁵⁹ Similarly, the location of the pathology (ie upper versus lower pole tumors), alter the location of the trocars. Obese patients present more of a challenge. In the morbidly obese patient, the pannus pushes the peritoneum anteriorly, thereby displacing the retroperitoneum more laterally. In this patient population, moving the trocar template laterally is usually required to optimize access and surgical performance.

After primary access is obtained, the next trocar site is for the camera. The camera trocar should be placed so that the cameraman is on the same side as the surgeon and both the surgeon and the cameraman are facing in the same direction. Having the cameraman and the surgeon standing on the same side of the patient, the surgeon is prevented from working in “reverse” or at an angle. Non-intuitive camera angles have been demonstrated to impair laparoscopic

performance. Indeed, a non-intuitive angle of vision will be particularly deleterious to the performance of the less experienced laparoscopic surgeon.⁶⁰

Compliance of the abdominal wall is different in each patient, and the insufflated abdomen may result in significant alteration of the external anatomy. As such, after insufflation, the surgeon should re-evaluate positions for trocar deployment. Even after trocars have all been deployed, the surgeon should feel comfortable adding additional 5-mm trocars at the time of surgery. Five mm trocars can be added liberally to optimize performance and outcome, and neither result in additional post-operative pain, nor require fascial closure. Once the surgical team is pleased with trocar deployment and the access for surgery, the insufflation tubing should be placed on any trocar other than the camera trocar, which minimizes its cooling effect and consequent lens fogging.

While care should be taken to position the trocars in an ideal configuration, this goal is not always achieved. Placing working trocars too close to each other causes rolling (instruments rubbing against each other inside the patient). Specifically, the instruments can contact the camera making ideal visualization of the surgical field challenging. To prevent the physical interaction of the camera with the working trocars, the trocars should be placed a minimum of 10cm apart.

Trocars should not be deployed through the rectus muscle. Deployment of trocars through the rectus muscle risks damage to the epigastric vessels. These vessels travel near the lateral edge of the rectus muscles in the lower abdomen and travel closer to the midline in the upper abdomen where they join

the internal mammary arteries. Generally if trocars are not placed in the midline, they should be placed at least 6cm lateral to the midline to prevent epigastric injury.

Transperitoneal renal surgery

For transperitoneal laparoscopic renal surgery, primary access is obtained approximately half way between the anterior superior iliac spine and the umbilicus. In obese patients however, the umbilicus is not a reliable landmark because it moves dependently with the panniculus. Therefore, in the obese patient, the primary access site and all other access sites should be moved laterally. In a non obese patient, a dilating 12mm trocar is placed at the primary access site which will then serve as the working trocar for the surgeon's left hand in right sided access and the surgeon's right hand in left sided access. A second 12mm trocar is placed lateral to the rectus muscle, in parallel to the primary access trocar but closer to the costal margin. A third dilating 12mm trocar is placed in the midline, midway between the two working trocars for the camera. This position will minimize the interaction of the laparoscope with the working instruments, and will provide the surgeon with the most intuitive working angles. The procedure is initiated with these three trocars. If a self retaining retractor is needed, a 5mm trocar is placed between the two working trocars in the posterior axillary line for this purpose. For right sided procedures, a 5mm trocar is often placed in the upper midline near the xyphoid process to accommodate a traumatic locking grasper forceps which can grasp the diaphragm and hold the

liver up exposing the upper pole of the kidney, adrenal and suprarenal vena cava. The figures below depict the left- and right-sided configurations for transperitoneal laparoscopic renal surgery.

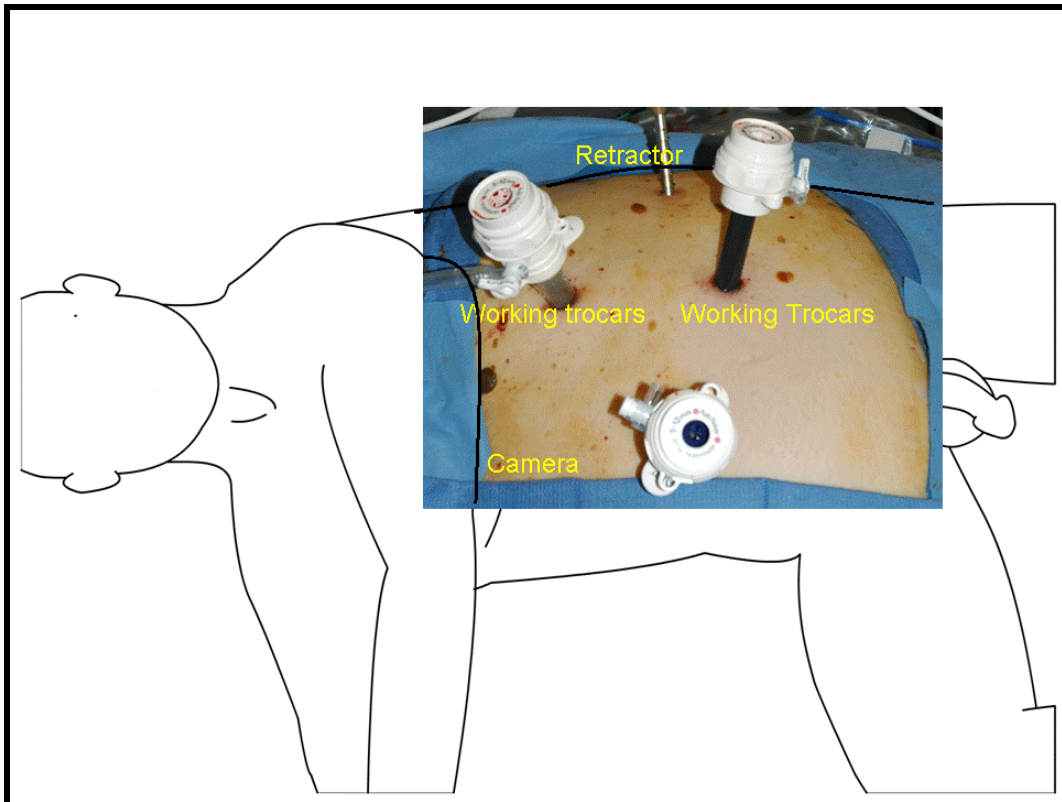


Figure 5. Trocar placement Left transperitoneal laparoscopic nephrectomy, labeled with the three 12mm trocars and one 5mm retractor trocar

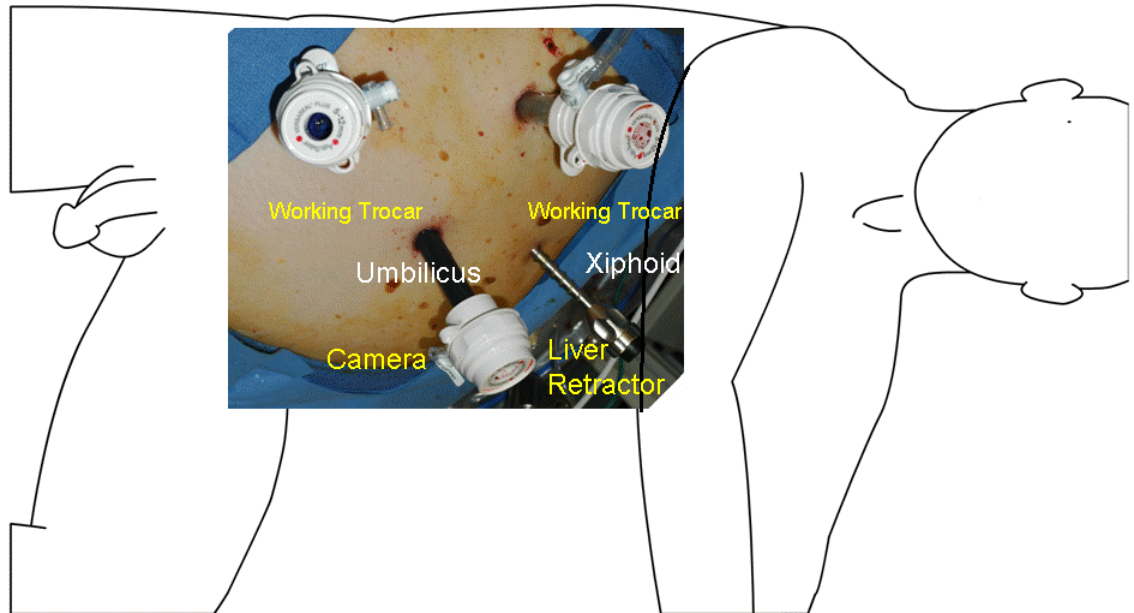


Figure 6. Trocar placement

Right transperitoneal laparoscopic nephrectomy

Retroperitoneal Renal Surgery

Retroperitoneal Primary Access

An open technique is used for accessing the retroperitoneum. Initial access is just below the tip of the 12th rib. After a 2cm skin incision is made, the posterior lumbodorsal fascia is incised and the muscles are bluntly split with the surgeon's index finger. The retroperitoneal space can then be entered bluntly with a finger or sharply with a Kelly clamp through the fascia. The index finger is used to confirm correct location by palpating the psoas, the lower pole of the

kidney and the undersurface of the 12th rib. Once the correct location is confirmed, a silastic balloon dilator (U.S. Surgical Corp./Tyco, Norwalk, CT) is used to open up the retroperitoneal space. The silicone balloon is inflated manually with a bulb insufflator (40 pumps) and to approximately 800 cc. The working space is created as the balloon displaces the peritoneum anteriorly.

An alternative approach published by McDougall and colleagues is to construct a dilating balloon with a 16F rubber catheter. The middle finger of a size 8 sterile latex surgeon's glove is cut off and tied over the tip of the rubber catheter with a 2-zero silk ligatures positioned such that the openings at the catheter tip were within the glove tip. The balloon catheter is back loaded through a 28F Amplatz sheath until the balloon was retracted to just inside the sheath. The assembled unit is inserted through a 12 mm. trocar until the tip of the Amplatz sheath lay just at the trocar opening. The balloon catheter is advanced approximately 2 to 3 cm into the perirenal fat and the balloon is filled with 600cc of normal saline. The fluid is then aspirated and the balloon catheter is removed along with the Amplatz sheath.⁶¹ After balloon dilation, the Autosuture™ Structural Balloon trocar (US Surgical, Norwalk, CT), or Hasson trocar is placed at the primary access site and the field is insufflated to 15mmHg.

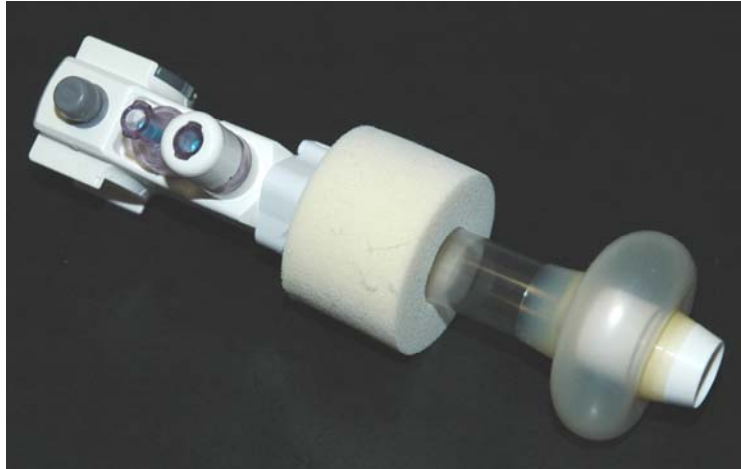

Figure 7.
Autosuture™ Structural Balloon trocar (US Surgical, Norwalk, CT)

After primary access has been gained at the tip of the twelfth rib, and a trocar has been deployed at this site, a second standard trocar is deployed just lateral to the paraspinous muscles at the costovertebral angle. This trocar can be deployed under direct vision by using a 30-degree lens. Using this second trocar for access, a 10-mm blunt instrument can then be used to gently peel the peritoneum forward and a third 12-mm trocar can be deployed anterior to the primary access site along the same line defined by the first two trocars. If necessary, a 5-mm trocar can be placed further anteriorly if a self retaining retractor is necessary. The figures below depict left-sided trocar configurations for retroperitoneal laparoscopic renal surgery.

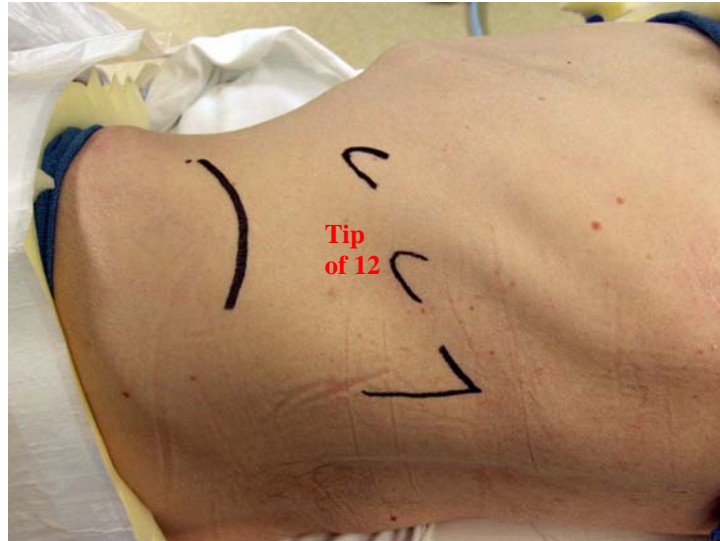


Figure 8a. Left retroperitoneal laparoscopic renal surgery
Marking for trocar placement for showing the tip of the twelfth rib, which is the primary access site

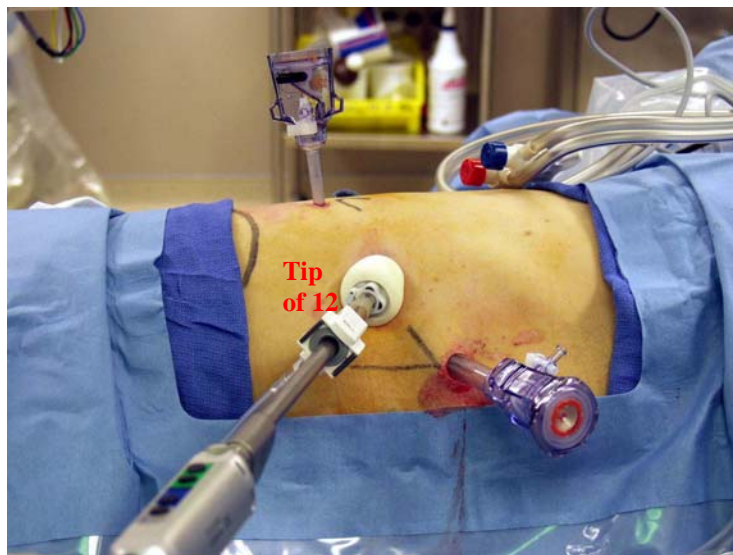


Figure 8b. Left retroperitoneal laparoscopic renal surgery
Balloon trocar is primary access at tip of the twelfth rib

Hand-assisted laparoscopic renal surgery (HAL)

Primary Access

There are several options for obtaining primary access. One option is to establish the pneumoperitoneum with the Veress needle technique, which is placed at the lateral border of the rectus sheath just caudad to the level of the umbilicus.⁶² Once the abdomen is insufflated to 15mm Hg, the Veress needle can then be converted to a 10 or 12 mm laparoscopic trocar and the remaining trocar, including the hand port, can be placed. A second method used is by starting directly with the hand-port placement and use it to insufflate the abdomen. An advantage of this method is the ability to insufflate at a faster rate of 30 L/min to a pressure of 15 mm Hg, whereas the Veress technique can only insufflate at 2.5 ml/minute.⁶³ Another advantage is that it allows the surgeon's hand to aid in retraction and mobilization of the peritoneal contents to aid in save trocar placement A third method is start with the Hasson technique, insufflate and then place the hand port.

Depending of the location for the hand port it can be placed with either a lateral, muscle splitting or a midline muscle sparring incision. The most used technique is via a periumbilical vertical incision through the anterior rectus fascia. The periumbilical incision avoids the more painful muscle splitting incision. The length of the hand-assist incision is the surgeon's glove size in centimeters. For example, a surgeon with a size eight glove should make an eight cm incision.

Secondary Access

Once the hand port access has been established, trocars are then placed to accommodate the camera and instruments. If the hand assist device is the primary access, then a laparoscope can be inserted directly through the hand-assist device while maintaining insufflation. In this way, additional trocars can be deployed under direct laparoscopic vision. Typically, the primary surgeon's non-dominant hand works through the hand-assist device and his or her dominant hand is used for fine tissue manipulation with a laparoscopic instrument.

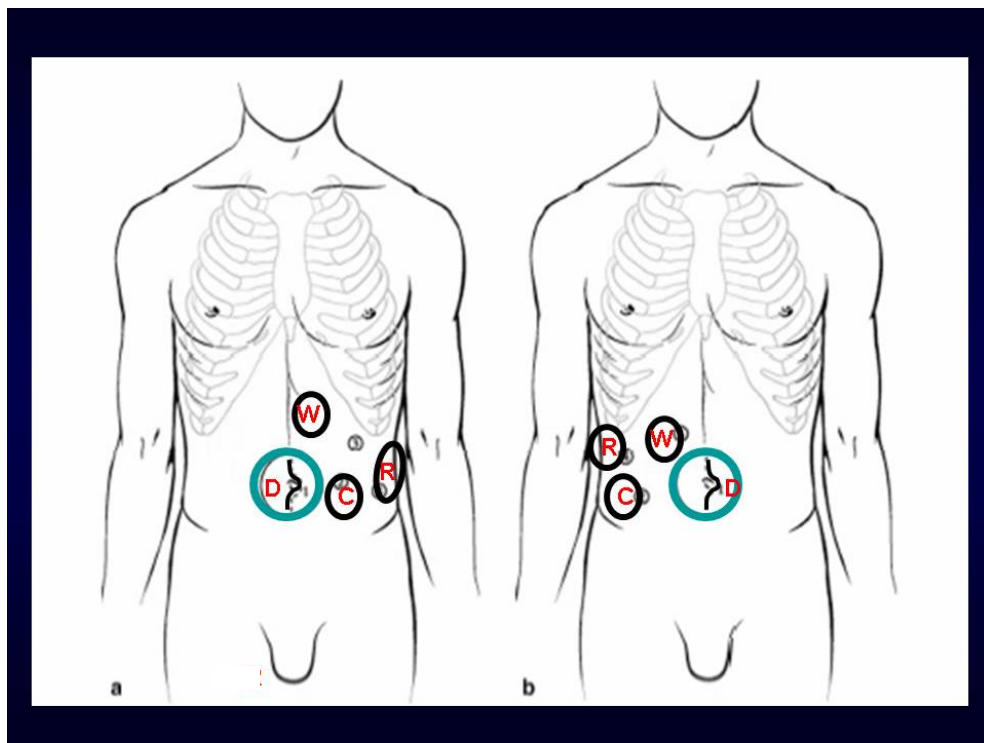


Fig 9.

a. Left sided Access for HAL b. Right sided access for HAL

C – Camera, D – Hand device, R – retractor, W – Working trocar

Dan, I have no idea what the letters stand for and neither will the reader.

Hand Assisted (HA) vs. Pure Transperitoneal (TP) Laparoscopic Nephrectomy

With hand-assisted laparoscopy, the hand can serve as a retractor, provide tactile feedback, can help to orient the surgeon to the two dimensional laparoscopic environment, and can be used to provide manual compression of bleeding if necessary. By enabling the surgeon's tactile senses, the hand-assisted technique is an excellent segue for the open surgeon to help facilitate his/her transition to laparoscopy, and the hand-assisted approach is significantly less invasive than open surgery.

There has been some controversy between the use of pure laparoscopy and hand-assisted laparoscopic technique for renal procedures. Indeed, the hand-assist device does facilitate the procedure for surgeons with less experience with laparoscopy, and hand-assisted laparoscopic renal procedures are still much less invasive than open procedures. HA is an attractive treatment option for even experienced laparoscopic surgeons in certain technically challenging circumstances. The application of hand-assisted laparoscopy allows for the successful laparoscopic completion of these cases with reasonable operative times, blood loss, and complications. HA may broaden the indications for a laparoscopic approach to cases that might otherwise have been performed with traditional open surgery.⁶⁴

There are several studies in the literature comparing HA and TP, demonstrating that a "pure" laparoscopic approach is less invasive and results in a faster, long-term convalescence compared to equivalent hand-assisted laparoscopic procedures.⁶⁵ Indeed Nadler and colleagues found that while the

HA approach had shorter operative times, the TP approach had a significantly shorter hospital stay than the HA approach (2.1 vs. 3.4, respectively). While it was not statistically significant, there were trends toward less time to oral intake and narcotic use in the TP group ($p = 0.19$ and 0.30 , respectively). Although a shorter operative time lowers OR costs in the HA approach, the lower overall hospital stay and postoperative morbidity of the TP approach offers a considerable advantage over HA.⁶⁶ In a study by Baldwin and co-workers, OR time for both the HA and TP were similar, but analgesia and convalescence were less for TP.⁶⁷ Finally, Nelson and Wolf found that although HA was associated with longer procedure times, with experience mean operative time decreased for standard but not for hand assisted laparoscopy.⁶⁸

Laparoscopic Radical Prostatectomy

Although robotic radical prostatectomy has to a large degree reduced interest in pure laparoscopic radical prostatectomy, the laparoscopic radical prostatectomy remains a minimally invasive alternative to radical open the radical retropubic prostatectomy. A total of five or six trocars are used in laparoscopic radical prostatectomy. Primary access is usually achieved with a Veress needle. A laparoscope is placed at the umbilicus and the remaining trocars are deployed under direct laparoscopic vision. In thin and light skinned patients, the light from the laparoscope can even be used to transilluminate the abdominal wall to minimize the risk of injury to the epigastric vessels. Two working trocars are deployed just lateral to the rectus muscles and just inferior to the umbilical

camera trocar. Two 5-mm trocars are then deployed near the anterior superior iliac spine bilaterally, and a 5-mm suprapubic trocar is sometimes deployed in the midline after mobilization of the bladder.⁶⁹

For robotic-assisted laparoscopic prostatectomy, similar templates have been devised. Typically, there are three robotic arms. Two 8mm trocars are dedicated to the robotic arm instrumentation, and an umbilical trocar is dedicated to the robotic camera lens. The remaining trocars are for the insertion of instruments by the laparoscopically astute assistant, for retracting, suctioning, and passing sutures.⁷⁰ The positioning for the assistant trocars are as follows: two 5mm trocars are placed bilaterally approximately 2 finger-breaths superior and medial to the ASIS. These trocars accommodate the suction-irrigator on the right and the self-retaining retractor or 4th robotic arm of the left. If necessary, a single 5mm trocar may be placed in the supra-pubic area for additional retraction.

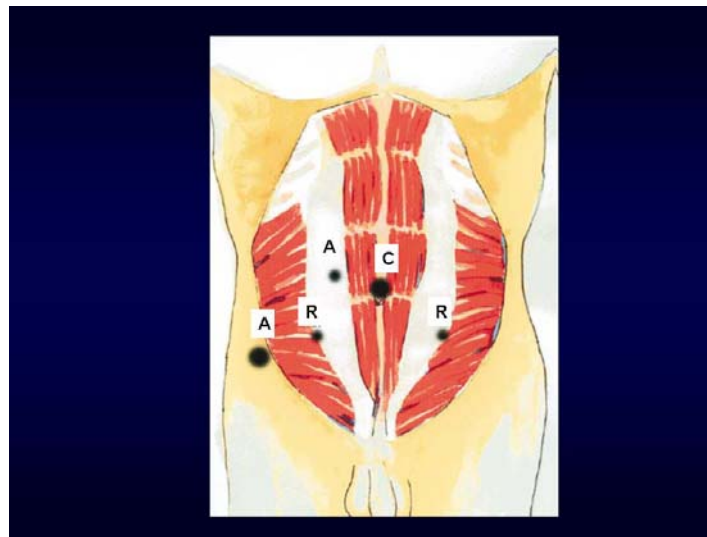


Figure 10.

Trocar placements for Robotic Prostatectomy, C Camera trocar, R robotic arms, A Assistant trocars⁷¹

CHAPTER 8 **INSTRUMENTATION**

Trocars


The word trocar is originally French meaning three sided. A trocar is a hollow cylinder with an access mechanism on one side which can be a blade (often three-sided), a plastic lip that is used for dilation, or a radial dilating mechanism (needle with sheath around it that is dilated when an obturator is pushed through the middle). On the external side of the trocar is a valve mechanism which allows instruments to be passed in and out of the patient's insufflated body cavity while maintaining the insufflated space. Trocars, also known as ports, usually have a valve to which insufflation tubing can be attached to maintain the insufflation pressure. Most trocars have an outer sheath (also called a cannula or trocar) and an inner obturator, which houses the access mechanisms.



Figure 11

Trocars are stratified into two major classes; cutting trocars and either axial or radial dilating trocars. Cutting trocars use a blade to penetrate the fascia. Recent data has clearly demonstrated that cutting trocars result in a higher

incidence of injury to the abdominal wall vasculature and, as such, the use of cutting trocars should be avoided. Dilating trocars, which penetrate the abdominal wall without the use of a blade, are also preferred as they produce a fascial defect one half the size of the diameter of the trocar (ie. 12-mm dilating trocar produces a 6-mm fascial defect). In contrast cutting trocars produce a fascial defect equal to the diameter of the trocar. As such, cutting trocar sites larger than 5mm should be closed in adults.



A. Cutting, single blade. B. Blunt, radial dilating. C. Cutting plastic blade. D. Cutting triangular blade. E. Hybrid dilating

Figure 12

When dilating trocars are applied, 12-mm trocar sites generally do not require fascial closure, as the defect is usually 6-mm or smaller. However, to minimize the risk of hernia formation, the surgeon should perform a digital inspection of each dilating trocar site (gently place the tip of the index finger in the defect). If the digital inspection allows for more than just the very tip of the index finger to penetrate the fascia, the site should be closed. In all patients who may have weak fascia (eg. malnourished patients, patients on steroids, etc.) all

fascial defects should be closed. Similarly, the pediatric population, all trocar sites including the 5mm cutting trocar sites should be closed to minimize the risk of hernia formation.

Robotic procedures use specialized dedicated 8mm cutting trocars. Since these are cutting trocars, the sites of these specialized trocars generally should be closed. At the surgeon's discretion, a Carter-Thomason CloseSure[®] System (Inlet, Trumbull, CT) can be used to close the working trocars. The umbilical trocar is extended 3cm to 4cm for specimen removal. The remaining assistant trocars, which are dilating trocars do not need to be closed, but it is prudent to palpate each site, and close the fascia if it can accept a small (5th) finger.⁷²

Monopolar and Bipolar energy

Some basic principles of electrosurgery are important. Electrosurgery is simply high-frequency electrical current passing through tissue to create a desired clinical effect. As the current is delivered, it passes through and heats the tissues. Electrosurgical generators can apply energy in either a monopolar or bipolar fashion. Monopolar energy requires that the current from the generator pass from the active electrode through the patient and out of the body through a dispersive electrode pad (grounding pad) connected to the generator to form a complete circuit. This differs from bipolar energy in that the active electrode and the return electrode are integrated into the energy delivery instrument (usually forceps) with the target tissue being grasped between to complete the circuit. Electrical current returns from the surgical site through the instrument rather than

running to a grounding pad on the patient. The local nature of the circuit makes bipolar energy more precise and less likely to cause collateral damage to adjacent tissues. Bipolar laparoscopic energy devices are generally safer and more hemostatic modality than when compared to monopolar energy devices.

Monopolar energy

The use of Monopolar energy is discouraged, because there is significant risk of collateral damage to surrounding structures. In a review of laparoscopic bowel injuries managed at Johns Hopkins, 50% of the injuries were associated with cauterization burns.⁷³ There are two types of monopolar energy damage that can occur. Direct coupling occurs when monopolar energy comes in contact with or arcs directly to a non-target structure such as the bowel or skin. Direct energy damage of this sort is usually easily identifiable by the surgeon as it happens. The second and more concerning type of energy, is capacitive coupling, which often occurs outside of the surgeon's field of vision. The electromagnetic field around the active electrode created by the alternating current induces electrical energy in any nearby parallel conductor. Small defects in the layer of electrical insulation surrounding the shaft of the active electrode allow energy to leak from the instrument during surgery. These instrument defects can be hard to detect, even with careful visual inspection. The reduced field of vision prevents the surgeon from seeing tissue away from the tip.

Despite the risks, monopolar energy devices are still commonly used by laparoscopic surgeons. Indeed, monopolar energy is used by >85% of surgeons

who perform laparoscopy.⁷⁴ The continued widespread use of monopolar energy is due to familiarity with these devices. Surgeons can also perform smooth cuts by using a continuous low-voltage current, fulgurate tissue with a damped current, or combine the two functions simply by varying the current or voltage level delivered to the tip of the active electrode.⁷⁵

To protect patients from stray currents that may be released through faulty insulation, the electroshield system was introduced. The electroshield system uses active electrode monitoring (AEM). AEM offers more safety by combining added electrical insulation, conductive shielding, and an electronic current monitoring system. The conductive shielding within the insulation itself becomes “capacitively coupled” to the active electrode, and not any metal surgical instruments or patient’s tissue, eliminating the incidence of tissue burns from capacitive coupling. The conductive sheath is electrically connected to the return electrode of the electrosurgical unit, allowing for harmless dissipation of capacitively coupled currents. If stray energy levels become sufficiently high to damage non-targeted tissues, the AEM circuit interrupts the flow of energy from the electrosurgical unit and sounds an alarm. Monopolar energy should only be used in laparoscopy in conjunction with the AEM system.

Ultrasonic instrumentation

Unlike monopolar and bipolar energy ultrasonic instruments rely on a vibrating metal blade with mechanical vibration at 55 kHz. The mechanical vibration results in tissue alterations that are different from those produced by

electrical energy. Ultrasonic energy sources result in less charring of tissue, less lateral energy spread, and less particulate plume (“smoke”) that can degrade the surgeon’s vision. Specifically, thermal damage to adjacent tissue is only histologically evident 0 -1mm from the site at which the device is activated.⁷³ Although all ultrasonic instruments function with the same basic mechanism, there are several studies establishing efficacy of one device over the other.^{76,77} Ultrasonic instrumentation is best used for sealing small to medium sized vessels, and has utility in both open and laparoscopic surgery.

There are several ultrasonic devices on the market. Ethicon makes the ACE™ and the HARMONIC SCALPEL® (Somerville, NJ). Olympus markets the Sonosurg™ (Melville, NY). Lastly, US surgical makes the AutoSonix™ (Norwalk, CT). Of the currently available vessel sealing devices, the harmonic scalpel offers the least collateral tissue damage and the fastest tissue trisection times.⁸¹ An example of the safety and efficacy of energy devices is the reported combined application of bipolar cautery and Harmonic Scalpel has been used in 160 consecutive laparoscopic donor nephrectomies to divide the branches of the left renal artery without complications.⁷⁸

Modified bipolar energy devices

One of the first modifications of energy devices in half a century is the LigaSure (Valley Lab, Boulder, CO) device. The electrothermal bipolar vessel sealer, EBVS, is FDA approved for use on arteries and veins up to 7 mm in diameter. The LigaSure device produces a hemostatic seal by applying high

current and low voltage, which differs from the energy used in standard monopolar and bipolar cautery (high voltage and low current). The system senses uses the end-effector to sense the impedance of the tissues within the jaw, and adjusts the voltage according to pre-defined protocols. The addition of extreme pressure applied by the instrument, which also differs from other energy sources, causes the denatured protein to reform, with the vessel walls in apposition.⁷⁹ Histologically, the internal elastic lamina is preserved, and collagen bundles form across the previous lumen. The instrument is available in various sizes for both open and laparoscopic surgery. The laparoscopic versions are either 5 or 10 mm. The 10-mm laparoscopic EBVS has a cutting blade within it for tissue transaction.

The LigaSure (Valley Lab, Boulder, CO) vessel sealing system utilizes bipolar energy that is modulated by the device in response to changes in impedance as the vessel wall is sealed.⁸⁰ Once the impedance monitor detects that the seal is complete, a brief period of cooling ensues. After the tissue cools and is ready to be divided, the surgeon is notified by an audible tone. The bipolar energy fuses collagen fibers within the vessel wall to produce a translucent seal.⁸⁰ In porcine investigations, the LigaSure vessel sealing system reliably sealed arteries up to 6mm and veins up to 12mm in diameter.⁸¹ The 10mm diameter device has been used to divide the bladder pedicles in open and laparoscopic surgery. The Atlas models include a knife blade within the device's jaws to divide tissue. Recently, another vessel sealing system has been introduced. The Enseal (SurgRx, Redwood City, Ca) uses a similar impedance

sensing system to adjust the devices voltage during activation. However, the device also has the capability to sense tissue in the end-effector itself and using heat-based technology distributes energy evenly to the tissues within the jaw. This system is promising, but no data exists to date regarding the Enseal's ability to seal vessels or the amount of lateral energy spread that is associated with this device.

Floating ball[®]

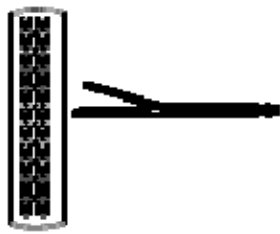
The Floating ball[®] (Tissue Link Medical Inc., Dover, NH) is a high density, water cooled, monopolar radiofrequency device. Room temperature sterile saline is dripped over the tissue at the surface of the device to cool the tissue and prevent charring. The device is useful for obtaining hemostasis on the cut surface of the kidney, liver and spleen. Laparoscopic partial nephrectomy without hilar control, using the Floating Ball for pre-coagulation prior to cutting has been reported, but anecdotal reports question the safety of this technique.^{82,}

⁸³ Indeed, with experience, it has become clear that the Floating Ball is an excellent adjunct for hemostasis during partial nephrectomy, but by itself it is inadequate for hemostasis during these challenging procedures.

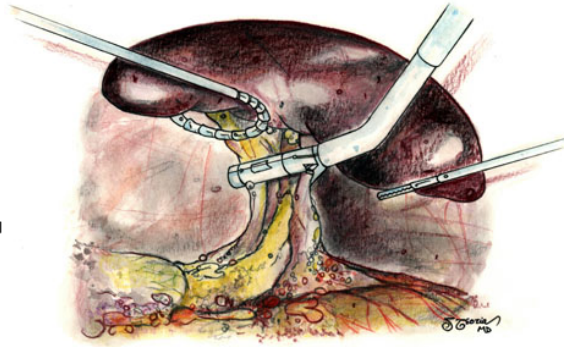
Staplers

The first applications of staplers were in open urological surgery to shorten lengthy procedure times. Stapling technology has been a particularly useful application during radical cystectomies, prostatectomies and nephrectomies. Due

to both short and long-term complications the first generation steel staples were replaced with staplers that use titanium staples. Today, in laparoscopy titanium staples are used for both tissue applications and for control of large vessels. Titanium has an excellent tissue and fluid biocompatibility and has been shown to be very compatible with the urinary tract without encrustation or induce stone formation.⁸⁴ Several Staplers are currently on the market. The Endo GIA by US surgical (Norwalk, CT) and the Endocutter by Ethicon Endosurgery (Sommerville, NJ) are two of the most commonly used devices. The Endo GIA comes in lengths ranging from 30mm to 100mm. The Endo GIA 30 can fit through a 12mm trocar and the larger Endo GIA 60 can fit through a 15mm trocar. This stapler delivers six staple lines and will cut between the third and fourth lines upon deployment of the incorporated blade mechanisms. The EndoPath is a disposable device with multiple color coded reloads. Each color is based on the size of the staples, with the 2.5mm (white) for vessels. Tissue loads are larger 3.8mm (blue) and 4.8 (green) for stapling thicker tissues. Care should be taken when using these staplers to keep the targeted tissues between the markers on the cartridges. This is especially true for vessel sealing, as a misfired stapler on a major vessel can have disastrous repercussions.



13a. Staple line



13b. Endo GIA across the renal hilum, *Teotia*,

Laparoscopic staplers with tissue loads have numerous applications in urologic laparoscopy. Staplers may be used for tissue applications such as bladder cuff transection during pure laparoscopic nephroureterectomy. In a report by Hattori and colleagues with three year follow-up, there was no statistically significant difference in cause-specific survival, bladder recurrence rates or extra-vesicle recurrence rates with this technique compared to open excision of the bladder cuff.⁸⁵ Seven year follow up of patients in whom titanium staples were used in the urinary tract show that encrustation and stone formation does not occur on titanium staples.⁸⁶ Similarly, titanium staples have also been used to reduce a redundant renal pelvis during laparoscopic pyeloplasty without evidence of stone formation.⁸⁷ It was once believed that a renal vein thrombus was a contraindication for laparoscopy. The contraindication of renal vein thrombus was due to the loss of tactile sensation during laparoscopy, and the inability to feel and milk the thrombus out of the jaws of the stapler. Recent studies suggest that in carefully selected patients, with endovascular staples,

laparoscopic resection of renal masses with level I renal vein thrombi is feasible.⁸⁸

Titanium Clips

Titanium clips have been shown to be as secure as traditional suture ligation when properly applied.⁸⁹ Proper control of a large vessel, such as the renal artery, includes placement of three clips on the “stay” side of the vessel and two clips on the “specimen” side. By applying five clips, which completely cover the diameter of the entire vessel, bleeding complications will be minimized.

A titanium clip can be fired over a staple line without problems. However, a stapler will malfunction if fired over a clip. To avoid this complication, titanium clips should be avoided or used sparingly in the area of the renal hilum where staplers may be fired. Laparoscopic staplers with vascular loads can be used to control large vessels such as the renal artery and vein. The seal produced with a vascular load stapler has been shown to be as secure as traditional suture ligation.⁸⁹

Locking clips

Non-absorbable polymer ligating clips with a locking mechanism at the tip are available. In a retrospective review of 50 hand-assisted laparoscopic donor nephrectomies in which two locking clips were used to control the renal artery and vein, no bleeding complications occurred.⁹⁰ A series of 246 laparoscopic nephrectomies from India in which Hem-o-lock clips (Teleflex Medical, Research

Triangle Park, NC) were used on the renal artery and vein, no clip-related complications were reported.⁹¹ However, a recent survey of surgeon-members of the American Society of Transplant Surgeons found that fatal and nonfatal hemorrhagic complications were more common when non-transfixing techniques, such as simple or locking clips, were used to control the renal artery rather than transfixing techniques, such as a suture ligature or a vascular stapler.⁹² This finding may be due to the application of just a single clip and cutting of the vessel precisely on the clip itself to optimize vascular length. When following the manufacturer's suggestion of using two clips and leaving a small cuff, the authors have found the Hem-o-lock clips very reliable. Indeed, these clips have a significantly reduced propensity to be avulsed off of vessels compared to standard titanium clips in the author's experience. The Hem-o-lock clip applicator requires a 10mm working trocar.

Vascular clamps

Presently, there exists a wide variety of vascular clamps which mimic the function of traditional open vascular instrumentation. Laparoscopic bulldog vascular clamps can be used to clamp the renal artery and vein during laparoscopic partial nephrectomy. The introduction of these clamps allowed for advanced laparoscopic partial nephrectomy to be performed.⁹³ Similarly, the introduction of laparoscopic Satinsky vascular clamps can be applied to facilitate vascular control during laparoscopic partial nephrectomy or for vascular repair of

vessels such as the vena cava. These clamps are also useful for management of renal tumors associated with a tumor thrombus.⁹⁴

Suture anchors

As laparoscopic reconstructive technique is technically challenging, suture anchors have been created. Suture anchors lock on to a piece of suture material and can act as an anchor or a knot. The Lapra-Ty[®] clip (Ethicon Endosurgery, Somerville, NJ) is an absorbable polydioxanone device designed to be secured to the ends of a suture thereby obviating the need for knot tying. Lapra-Ty clips have been used to facilitate closure of the renal defect after laparoscopic partial nephrectomy.⁹⁵ Use of the Lapra-Ty clip to close the renal collecting system should not be considered as there have been reports of the clips migrating into the renal collecting system after laparoscopic partial nephrectomy.⁹⁶

The Lapra-Ty clip applicator requires a 10mm trocar for passage. Other laparoscopic clips have also been used for suture anchoring. In a recent publication, Ames and colleagues compared the, Endoclip II[®] (US Surgical), Horizon Ligating Clips[®] (Weck), Hem-o-lok Medium Polymer Clips[®] (Weck), and a novel Suture-clip (Applied Medical) as suture anchors. In this *in vitro* study, the holding strength was greatest with the Lapra-Ty[®] clips.⁹⁷

Surgical pharmaceuticals

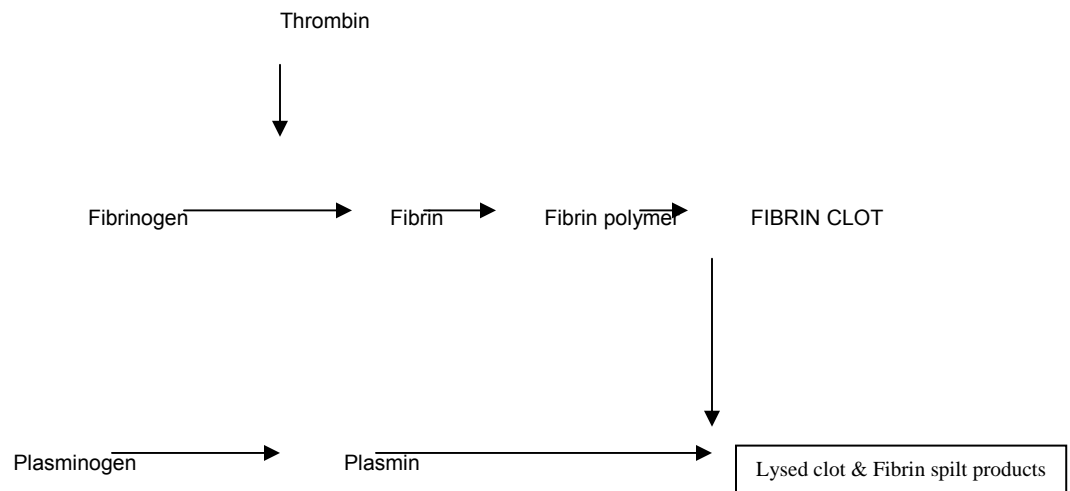
Control of blood loss during laparoscopy is paramount to the success of patient recovery. Hemostatic agents and tissue sealants are used routinely to

prevent excess blood loss. While these agents are useful adjuncts to other more traditional hemostatic techniques such as suture ligation of bleeding sites, surgical pharmaceuticals can not be relied upon alone to stop any type of significant bleeding. Some of the available products include thrombin sealant, fibrin glue, bovine serum/albumin/glutaraldehyde, and gelatin matrix. All differ in mechanism, cost, and application. Complications can include allergic reactions or thromboembolism and the risk of contracting hepatitis and bovine spongiform encephalitis or hepatitis.⁹⁸ The benefits and risks of use of these agents versus conventional treatment need to be considered on a case-by-case basis by the surgeon. The market remains replete with several companies, including Focal (Genzyme Biosurgery), Angiotech BioMaterials (Cohesion Technologies), Fusion Medical, Confluent Surgical, CryoLife, Medchem (C.R. Bard), Tissuemed, Surgical Sealants, Ethicon/Closure Medical, U.S. Surgical (Tyco Group), GEM srl. Sadly, while thousands of manuscripts have been published on surgical pharmaceuticals, very few prospective randomized trials have been performed. As such, the true utility of most of these products remains unknown. Additionally, due to the lack of available evidence, these products are very commonly overused and misused.

Hemostatic Agents

A number of hemostatic agents are clinically available that utilize various mechanisms for hemostasis. The majority of these agents use the terminal portion of the natural clotting mechanism to enhance local coagulation. As shown

below, the combination of applied or autologous thrombin to cleave fibrinogen into fibrin monomers is the primary mechanism of action of most of the available hemostatics. The fibrin monomers polymerize to form a stable fibrin clot. Over time, the clot is then reabsorbed by the action of plasmin. In addition, it is also responsible for the aggregation of blood platelets in the formation of the "platelet plug" as well as the activation of factor VIII, Factor V, Factor XI, Factor XIII, and Protein C.



Fibrin “glue” or fibrin “sealant products” exist from various manufacturers (Tisseel, Baxter HC, Glendale, CA). The term fibrin sealant should not be used as there is no evidence that additional of fibrin-based products improves sealing in the urinary tract. Indeed, studies indicate that the fibrin-based products may impede formation of granulation tissue and wound healing in the urinary tract.⁹⁹ When used on the urothelium in a porcine model, Vanlangendonck and colleagues found that fibrin glue caused a narrowing of dense fibrosis at the

anastomosis with mild acute and chronic cellular infiltrate and focal areas of fibrosis.¹⁰⁰

The fibrin glue products are simply a combination of fibrinogen and thrombin which are kept separate until they reach the target site. Usually these formulations include calcium ions and enzymes to regulate the rate of fibrinolysis. These products have been used on cut parenchymal surfaces such as the kidney, spleen or liver. Fibrin “glues” or “sealants” may also be used on small, low-pressure and low-volume bleeding sites for adjunctive control with compression and other hemostatic modalities. Calcium chloride is added to fibrin products to promote coagulation, and Aprotinin is added to stabilize the clot by delaying the action of plasmin. The two main components of the fibrin glue (fibrinogen and thrombin) are delivered through separate channels of a specially designed elongated catheter (i.e. Duplocath 35 M.I.S., Baxter HC, Glendale, CA) until they combine at the tip of the delivery system thereby creating the glue.

To avoid a risk of allergic-anaphylactoid reaction and/or thromboembolic events, which may be life threatening, no hemostatic agents should be injected into a vessel or directly into tissue. As Tisseel Fibrin Sealant is made from human plasma, it may contain infectious agents, such as viruses.¹⁰¹ A collagen sheet may be utilized in conjunction with Tisseel (Collagen Sponge, Bard, Glendale, CA, or Helistat, Colla-Tec, Inc. Plainsboro, N.J.). While fibrin glue products are commonly used for hemostasis, they are not as effective as other agents such as Floseal. Indeed, the comparative limited hemostatic ability of

fibrin glue products, and the lack of “sealant” capability, makes the applications of fibrin glue products in urology very limited.

Another hemostatic compound is Floseal (Baxter HC, Glendale, CA). Floseal consists of collagen beads with thrombin. Floseal requires the presence of the patient’s own fibrinogen from their own exposed blood to create a hemostatic coagulum. Floseal is a dedicated hemostatic product, which functions by three mechanisms. First, the collagen granules expand by hydration from blood and work into irregular surfaces such as the cut surface of the kidney to yield local micro-compression. This property helps to secure Floseal to vertical surfaces and prevent “run down”. Second, an absorbable bolster is placed over the Floseal and direct pressure or “macro-compression” is applied by the surgeon. Finally, the collagen beads of the Floseal are coated with thrombin which makes contact with and cleaves the fibrinogen in the patient’s own blood to create a bland fibrin clot. Floseal decreases hemorrhagic complications when used during laparoscopic partial nephrectomy.¹⁰²

CoSeal surgical sealant is a hemostatic substance, commercially available from Baxter pharmaceuticals, which form when two distinct polyethylene glycol polymers chemically bind together. When the polymers from two syringes are combined and applied to tissue, a synthetic hydrogel forms that provides hemostasis. The hydrogel reabsorbs over a few weeks. There are no known contraindications to the use of CoSeal. However, the substance may adhere to tissues (other than those for which it is intended) or cause a local inflammatory response. As with any hemostatic agent, it should not be injected into a vessel

as it may cause thromboembolization. A recent porcine study, however, found that CoSeal was not as effective in adhering to the cut surface of the kidney as Tisseel.¹⁰³

Bioglue is a product composed of purified bovine serum albumin (BSA) and glutaraldehyde. The glutaraldehyde molecules covalently bond (cross-link) the BSA molecules to each other. Bioglue also covalently bonds the proteins within the tissue at the site where it is applied. This creates a mechanical seal that does not rely upon the patient's own clotting mechanisms. Bioglue may cause local allergic reactions so repeated use should be avoided. It should not be peeled off as this may damage the underlying tissue. Bioglue is neurotoxin so it should not be applied near nerves. As with any hemostatic agent, it should not be injected into a vessel as it may cause thromboembolization.¹⁰⁴ Regarding hemostasis, BioGlue was originally designed for closure of small vascular defects during anastomoses. Application for parenchymal bleeding such as with partial nephrectomy has not been verified. Similarly, there is no evidence that BioGlue is a sealant in the human urinary tract. Indeed in a recent porcine study, reinforcement of laparoscopically sutured vesicourethral anastomoses with Bioglue actually impaired wound healing on histological analysis when compared with a laparoscopically sutured vesicourethral anastomosis alone.¹⁰⁵

Mechanical hemostatic agents

Surgicel, Surgicel Fibrillar, and Surgicel NU-KNIT (Ethicon, sumerville, NJ) are regenerated, oxidized cellulose which is supplied in a sheet form. Surgicel

provides a surface on which the patient's own intrinsic clotting mechanisms act to form a clot. These products are produced from plant material so there is no risk of transmission of animal or human pathogens. They reabsorb in 7-14 days and have been in use clinically for over 30 years. These products are particularly useful when formed into a bolster. To give extra volume and a larger bolster, these products can be wrapped around Gelfoam.

Gelfoam (Pharmacia and Upjohn Company, Kalamazoo, MI) is an absorbable sponge-like substance which is believed to promote hemostasis by physical occlusion of bleeding vessels. It does not appear to directly alter clotting mechanisms. The interstices of Gelfoam hold a significant amount of blood and fluid. Gelfoam is often used in combination with thrombin spray and/or Surgicel.¹⁰⁶

Retractors

Just as with open surgery, exposure is frequently the key to elegant and precise dissection. In laparoscopic surgery where the surgeon is limited to two working instruments (can not use the hand for multiple activities such as simultaneous retraction and dissection) the application of fixed retractors can be very important to optimize exposure and dissection.

One frequently applied combination is the application of a fixed retractor arm, the Endoholder (Codman, Raynham, MA), and a Padron endoscopic exposing retractor (PEER retractor). This combination can provide a safe and effective means of self-retaining retraction during laparoscopic surgery




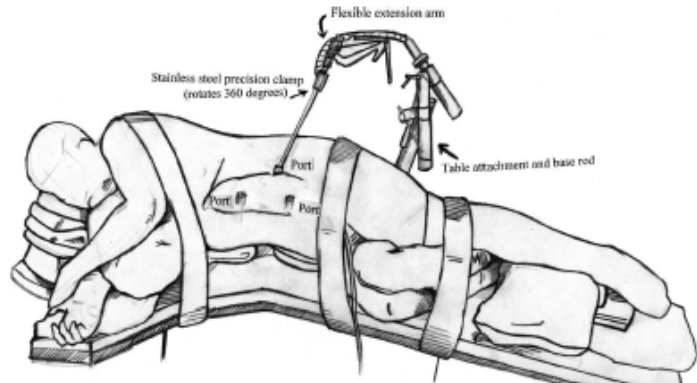
Figure 14a



14b

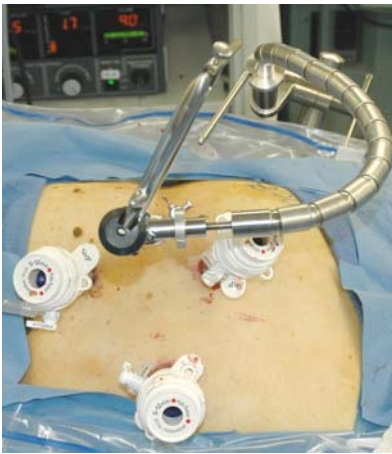

Fig 14c



14d

The fixed retractor system has four components: a table attachment; a base rod with couplings; a flexible, spring-loaded articulating arm; and a precision clamp which can hold a variety of instruments. The system provides excellent exposure. When used in over 200 cases, the only complication experienced was a single minor liver laceration.¹⁰⁷

Hand-assist devices

Hand-assist devices allow the surgeon's hand access to the abdomen during hand-assisted laparoscopic surgery. The Gelport (Applied Medical, Rancho Santa Margarita, Calif.) and the LapDisc (Ethicon Endosurgery,

Cincinnati, Ohio) are the most recent generation of hand-assist devices (HADs). The Gelport utilizes a synthetic sleeve with 2 incorporated rings. One ring is placed within the abdominal incision, which is made wide enough to fit the surgeon's hand. The length of the incision should match the surgeon's glove size (A surgeon with a size eight glove should use an 8 cm incision). A larger incision may cause poor fitting of the device and leakage of the pneumoperitoneum. The other ring snaps onto the Gelport which uses a biocompatible gel as a valve mechanism to allow the hand and instruments in and out of the peritoneal cavity while still maintaining the pneumoperitoneum.



Figure 15. The Gelport (Applied Medical, Rancho Santa Margarita, Calif)

The LapDisc works similarly but, it uses three rings. One ring sits inside the abdominal cavity as an anchor. The other two rings remain outside the abdominal cavity and, using a ratcheting mechanism, create a locking iris which can be opened and closed to seal around the surgeon's hand, instrumentation, or seal off completely. An evaluation of the two devices at Washington University found that both devices decreased blood flow to the surgeon's hand and caused

discomfort.¹⁰⁸ However, the Gelport was associated with more hand pain and caused a greater reduction in blood flow.

CHAPTER 9
TECHNIQUE FOR TRANSPERITONEAL LAPAROSCOPIC RADICAL
NEPHRECTOMY

Step 1: Patient positioning

The patient is positioned in the flank position with the umbilicus at the edge of the surgical table as described in Chapter 3. The side of the pathology should be the “up” side, and proper laterality must be confirmed with the patient’s imaging studies which must be available in the operating room at the time of the procedure.

Step 2: Access

Primary Access and secondary access – see Ch. 7

Step 3: Trocar placement

The remaining trocars are placed under direct vision as described in Chapter 7. Templates for the right and left sided configurations are also depicted in figures 5 and 6. These templates should be considered rough guidelines as each patient’s pathology and anatomy is different.

Step 4: Bowel mobilization

The colon is mobilized by incising the parietal peritoneum lateral to the colon and developing the plane between the mesocolon and Gerota’s fascia.

The parietal peritoneum contains visible capillaries that run laterally from the edge of the colon to the abdominal sidewall. Usually gentle traction will allow the surgeon to slide the peritoneal attachments of the colon over Gerota's fascia to help suggest the proper plane of incision. The mesocolonic fat is bright yellow Gerota's fascia has a much more pale yellow appearance. Recognizing this color distinction will help the surgeon stay in the correct plane. Similarly, when the surgeon remains in the plane between mesentery and Gerota's fascia, the dissection should proceed in an almost bloodless field. Bipolar cautery and the Harmonic scalpel are useful for this dissection. If bleeding or oozing are noted, it is likely that the surgical dissection has "drifted" into the mesenteric plane or even, occasionally, through Gerota's fascia into the perinephric fat. Re-evaluation of the surgical plane or proceeding in an alternative site may help to re-establish the proper dissection plane.

On the left, the incision in the parietal peritoneum is extended lateral to the spleen until the greater curvature of the stomach or the diaphragm is encountered. The spleen and pancreas are dissected from Gerota's fascia overlying the upper pole of the kidney until the spleen completely falls, by gravity alone, to the bottom of the field (medially in the lateral decubitus position). Extensive mobilization of the spleen in this manner protects the spleen during subsequent steps of the procedure and enhances the working space during the critical hilar dissection.

On the right side, after mobilization of the colon from the hepatic flexure to the iliac vessels, the surgeon should actively seek out the duodenum. While

typically easy to identify, the duodenum may be flattened against Gerota's fascia and difficult to discern. Actively identifying the duodenum will minimize the risk of duodenal injury. A Kocher maneuver is performed which usually expeditiously exposes the vena cava. Often the liver obscures the renal hilum and supra-renal vena cava. In these cases, the parietal peritoneum overlying the upper pole of the right kidney is incised with the Harmonic scalpel at the point where it meets the liver edge. The attachments of the liver to the diaphragm are also divided. A 5 mm trocar is placed in the upper midline near the xyphoid process, and a locking grasper is placed through this trocar, under the liver edge, and attached to the diaphragm. In this manner the liver is retracted cephalad, exposing the upper pole of the right kidney. This simple maneuver is used in most right sided laparoscopic nephrectomies and can greatly facilitate the most challenging components of the procedure including the hilar dissection and the dissection around the adrenal gland.

Step 5: Lower pole dissection

Before turning attention to the renal hilum, the lower pole of the kidney is dissected. By mobilizing the lower pole prior to the hilar dissection, the surgeon can have two angles of approach to the renal artery and vein (inferior and lateral) which can greatly facilitate the hilar dissection. This maneuver is particularly useful to facilitate identification and dissection of the renal artery which is usually behind the renal vein.

At the lower pole of the kidney, the ureter and gonadal vein is identified. In the upper 1/3 of its course, the gonadal vein is medial to the ureter. The left gonadal vein normally enters the left renal vein. Frequently, the renal vein can be dissected just lateral to the insertion of the gonadal vein to preserve this structure. However, if the gonadal vein interferes with adequate access to the renal hilum it may be clipped and divided. A plane is created medial to the gonadal vein and ureter and continued until the psoas muscle is encountered. Transection of the gonadal vein in the male may result in transient testicular pain in the post-operative period. On the left side, the renal vein has three insertions; the lumbar, which enters the vein posteriorly, the gonadal vein, which enters the renal vein inferiorly and the adrenal vein, which enters the renal vein superiorly. During the dissection, it is important to be mindful of the adrenal vein, as it typically enters the renal vein medial to the gonadal vein's insertion. Knowing where to look for these veins is vital for preventing vascular injury and minimizing blood loss. If carefully dissected, all these veins may be controlled with titanium clips or LigaSure. The most insidious of the three tributaries into the left renal vein is the lumbar vein. The lumbar vein is posterior to the renal vein and can result in significant bleeding if torn or avulsed. A careful search for the lumbar vein will minimize the risk of hemorrhage.

On the right side, the gonadal vein enters the vena cava near the lower pole of the kidney so it is usually preserved. For right sided dissections, the PEER retractor is placed under the ureter and lower pole of the kidney within Gerota's fascia and the retractor is secured with an Endoholder. On the left the

PEER is placed under both the ureter and gonadal vein. This maneuver opens the space medial to the lower pole of the kidney and allows the surgeon to follow the ureter or gonadal vein to the renal hilum.

Step 6: Hilar dissection

Careful review of the preoperative imaging will often reveal the number of renal arteries and veins and their relationship to one another. Having the images in the operating room at the time of surgery is of paramount importance, as the images can act as a guide for the surgeon during the dissection. The renal artery is generally posterior to the renal vein. Knowledge of its posterior location and whether it is above or below the vein is useful in guiding the surgical approach. Multiple renal arteries are more common than multiple renal veins with accessory lower pole arteries being the most common variant. In an effort to describe the feasibility of selective segmental artery clamping, Weld and colleagues, using a cadaver model, found that 51% of cadavers had an accessible pre-segmental artery. The posterior segmental is the most accessible segmental and the most common overall renal anomaly is a lower pole segmental.¹⁰⁹ Such information may allow laparoscopic partial nephrectomy to be performed with only segmental control, allowing minimal ischemic risk to the kidney remnant.

A successful hilar dissection is completely facilitated by proper dissection and exposure. Dissection of the entire lower pole inferiorly, and medial dissection of the vena cava, permit the surgeon to have wide access to the hilar

area and thus to optimize exposure. Working in “a hole” can make the hilar dissection very challenging and dangerous, and therefore should be avoided.

Once proper exposure has been obtained by proper dissection aided by the application of a fixed retractor system (Chapter 8), the hilar dissection is often easy and straightforward. If clips are used, a stapler must not be fired over the clips or malfunction of the stapling device will occur. Specifically, the stapler may fail to fire or may “jam” on the vessel and not be able to be removed.

A window should be developed on either side of the artery and vein to accept the stapler. The endo-GIA stapler with the vascular load is used to divide the renal artery. To ensure that no other renal artery exists, the renal vein may be gently occluded with an atraumatic grasper such as an Aesculap macrobipolar grasper. If the arterial supply of the kidney has been completely interrupted, the renal vein will remain decompressed and flat proximally and the kidney should remain blanched after division of the artery. If the vein does not decompress or the kidney remains pink, another artery is present. This must be identified and divided before the vein is divided or troublesome bleeding and engorgement of the kidney will occur. If there is any question as to additional blood supply to the kidney, a laparoscopic duplex ultrasound, if available, is very useful in confirming complete interruption of the arterial supply.

Step 7: Adrenal dissection

The adrenal gland should be taken selectively based on the surgeon’s discretion of oncologic control. When the surgeon wishes to spare the adrenal

gland, the harmonic scalpel and bipolar forceps can be used to create the plane between the adrenal and the upper pole of the kidney. If the adrenal is to be removed, the adrenal vein should be identified and divided with titanium clips or LigaSure. On the left side, identification of the adrenal vein is typically done while dissecting the renal vein. On the right, the adrenal vein is identified cephalad to the renal vein, and it is usually located in a relatively dorsal position. Once the adrenal vein is divided, the bipolar and harmonic scalpels are used to dissect the adrenal away from the liver and vena cava on the right and the tail of the pancreas and the aorta on the left.

Step 8: Posterior & lateral dissection

The attachments of the kidney to the diaphragm, psoas and quadratus muscle can usually be divided bluntly after any remaining peritoneal attachments are divided with the harmonic scalpel or any other transecting device. The location of the great vessels, renal hilum, vena cava, aorta, liver, pancreas and spleen must be known at all time to prevent inadvertent injury to these structures while freeing the last attachments to the kidney.

Step 9: Entrapment

For smaller specimens a 10mm Endo Catch™ (Auto Suture, Norwalk, CT) entrapment sack is used. It can be placed directly through a 12 mm trocar. For larger specimens, the most inferior trocar is removed. A 15mm Endo Catch entrapment sack is placed through this site. The specimen is placed above the

liver on the right or above the spleen on the left. This allows the sack to be placed below the specimen and facilitates its removal. The bag is closed, and the closure string is passed into the abdomen.



Figure 16. A 15mm Endo Catch

Step 10: Specimen removal and closure

The specimen may be extracted through a midline, lower quadrant or Pfannenstiel incision based on surgeon preference. The fascia of this incision is closed with running or continuous suture. The skin incisions are closed with suture and steri-strips or a skin adhesive such as Dermabond (Ethicon Endosurgery, Cincinnati, OH) or Indermil (US Surgical, Norwalk, CT). Sterile dressings are applied if subcuticular sutures have been used to close the skin. If the skin has been closed with an adhesive, dressings are contraindicated.

Step 11: Exiting the abdomen

The abdomen is insufflated again. Under low insufflation pressure, the abdomen is examined for bleeding. Any residual blood is suctioned from the abdomen. If there is any suspicion of bleeding, irrigation of the area of the field with sterile saline will help resolve the question. Small bleeding sites produce “rivulettes” of blood in the irrigant which can be identified. After hemostasis has been confirmed, all trocar are removed under direct vision and the sites undergo a “digital inspection” with the tip of the index finger. Any site that accepts a finger is closed even when dilating trocars have been used. When removing dilating trocars, a brief period of spontaneous closure should be allowed before performing the digital inspection as the fascial opening significantly contracts and decreases in size within one minute of removal of the trocar.

CHAPTER 10

COMPLICATIONS OF LAPAROSCOPIC SURGERY

The reported rates of complications with laparoscopic surgery vary widely.^{110, 111, 112, 113, 114} However, overall complication rates as high as 16 percent and mortality rates as high as 0.9 percent have been reported. According the Food and Drug Administration's (FDA) Manufacturer and User Facility Device Experience (MAUDA) database, most fatal injuries associated with laparoscopic equipment involved trocars,¹¹⁵ and all reported fatalities were due to vascular or bowel injuries. It is imperative that steps be taken to prevent complications. When complications do occur, they should be recognized early and managed properly to avoid further untoward effects.

Neuromuscular injuries

Proper patient positioning as described in Ch. 5, helps prevent neuromuscular injuries. Surgical time greater than 5 hours is a risk factor for all neuromuscular injuries except abdominal wall cutaneous neuralgias which are likely related to direct surgical trauma at trocar sites.¹¹⁶ Such cutaneous neuralgias occur in up to 3.6% of cases. Proper positioning and padding are the best ways of avoiding such injuries.

During renal surgery proper placement of an axillary roll helps prevent brachial plexus injuries at the lower shoulder. The upper arm should not be abducted more than 90 degrees and should not be externally rotated as this can

cause the head of the humerus to impinge upon the brachial plexus.¹¹⁰ The bed should only be flexed as much as is necessary to open the space between the iliac crest and the lower ribs as there is a trend towards more neuromuscular injuries when the bed is flexed.⁴⁸

Brachial plexus injuries can also occur when shoulder braces are used in combination with extreme lithotomy position. It is preferable to secure the chest with tape and the legs with stirrup and eliminate the use of shoulder braces entirely.¹¹⁷

Peroneal nerve injuries can be avoided by proper padding of the lateral surface of the leg and ensuring that the weight of the lower leg rests upon the heel rather than the lateral surface of the leg.

Lower limb compartment syndrome after prolonged laparoscopic procedures performed in the lithotomy position is a rare but potentially devastating complication. For procedures where elevation is prolonged, it has been suggested that the legs should be lowered every two hours. When positioning patients, dorsiflexion of the ankle should be avoided and adequate padding around pressure points should be used. Staff should be aware that any degree of Trendelenberg positioning may also increase compartment pressures.¹¹⁸

Rhabdomyolysis has been reported with prolonged extreme lithotomy position and with laparoscopy in the flank position. Risks factors include: prolonged operative time, increased body weight (particularly large muscular patients), use of the kidney rest, and male gender.^{119 48} Rhabdomyolysis

presents as acute muscular pain immediately postoperatively. In patients who have had laparoscopic renal surgery in the flank position, this pain presents in the “downside” gluteal area. Six of 7 patients at Washington University who presented developed postoperative rhabdomyolysis were positioned with the kidney rest up. “Tea-colored” urine may occur due to the presence of myoglobin in the urine. Classically, myoglobinuria produces a positive urinary dipstick analysis for blood in the absence of red blood cells on microscopy. If there is evidence of compartment syndrome in the gluteal muscles or elsewhere, general, vascular or orthopedic surgery consultation is warranted as fasciotomy may be necessary. Acute renal failure occurs in the majority of patients with rhabdomyolysis. Treatment includes hydration, diuretics and alkalinization. Dialysis may be necessary in those patients with renal failure.

Vascular injuries

Major vascular injuries (MVIs) are reported in only 0.05% of laparoscopic cases, with a mortality rate of 8%.^{120 121 122} Approximately 75% of MVIs associated with laparoscopy occur while obtaining access. The remaining 25% occur during dissection.^{123 121} Major vascular injuries account for 81% of deaths associated with laparoscopy as reported to the FDA by manufactures of laparoscopic equipment.¹²⁴ The open (Hasson) access technique does not completely eliminate the risk of MVI during assess.^{125 126}

A MVI during access may present as blood aspirated from a Veress needle. In this situation, the needle should not be insufflated as this may cause

CO² embolization and the surgeon should resist the temptation to remove the needle as it can be used to help identify the site of injury once access has been successfully gained. CO² embolization presents as sudden circulatory collapse during access, deep cyanosis of the head and upper extremities, elevated right heart pressures and CVP, and a “millwheel” murmur. Treatment involved stopping insufflation and desufflating the abdomen, placing the patient in the left lateral decubitus position (right side up) with the head down to trap the CO² bubble at the apex of the right ventricle where it is less obstructive, aspirating the CO² bubble with a central venous catheter, and cardiopulmonary bypass.

A MVI may also present as blood filling a trocar. In this situation the trocar should not be removed and should not be connected to insufflation. Leaving the trocar in place will tamponade the injury, and will help the surgeon to identify the site of injury. Unlike the smaller diameter Veress needle, a vascular injury caused by trocar placement should be treated by an open exploration which is usually best performed via a midline laparotomy incision. In a review of major vascular injuries that occurred during laparoscopic access, 5 of 6 patients who were managed without laparotomy died.^{127 128 129 130 121} Proximal and distal vascular control should be obtained, and then the trocar can be removed and the vessel can be repaired.

A MVI may also present more subtly. A retroperitoneal or mesenteric hematoma may be the only sign of the injury. If a MVI is noted during dissection and the patient is hemodynamically stable, the surgeon can attempt to manage the situation laparoscopically, conversion to an open procedure is not mandatory.

Recently, an external iliac artery transaction during a laparoscopic prostatectomy was managed laparoscopically with re-anastomosis yielding good results.¹³¹

This case is reportable as it is remarkable and the repair was performed by a very experienced laparoscopic surgeon. Patient safety is always the first priority, and maintaining a minimally invasive approach should always be secondary. As such, despite such reports, if faced with a major vascular injury, a surgeon should not hesitate to convert to an open procedure and obtain vascular surgery consultation if necessary.

Epigastric vessel injuries may occur when a trocar is passed through the rectus muscle. To avoid this injury, a trocar should be placed at least 6cm from the midline if it is not in the midline. Trocar injuries may occur during primary access but should not occur with placement of the secondary trocars, as these placements should be performed under vision. Use of optical trocars for primary access is associated with few complications.¹³² As the trocar may tamponade bleeding, it is imperative to remove trocars under direct vision and low insufflation pressure. If bleeding is noted, a figure-of-eight suture may be placed through the fascia and vessel utilizing a Carter-Thompson or other type of closing tool can adequately control abdominal wall bleeding.

Bowel injuries

In the literature, bowel injuries are reported in 0.13 - 0.9% of laparoscopic cases.¹³³ 50% of bowel injuries are caused by cautery.⁷³ Trocar and Veress needle injuries to the bowel are also common.¹³⁴ The majority (67%) of bowel

injuries are not recognized intra-operatively.⁷³ Bowel injuries that are recognized post-operatively present quite differently than the traditional presentation that is typical perforated viscous. Single trocar-site pain, abdominal distention, diarrhea and leukopenia are the presenting symptoms.¹³³ Computed tomography (CT) with oral contrast should be obtained if a bowel injury is suspected postoperatively. If the CT scan does not demonstrate signs of a bowel injury such as a gross leak or thickening of the bowel, a delayed film should be obtained six hours later to increase the probability of identifying a site of bowel perforation. Laparoscopic bowel injuries are associated with significant mortality, 3.6%.¹³⁴ If there is not a high index of suspicion for bowel injury, and the surgeon does not look for the signs of laparoscopic bowel injury as just described, patients will have a high mortality rate. It is absolutely critical to know that the traditional acute abdomen, with peritoneal signs and leukocytosis, is not seen characteristic of laparoscopic bowel injuries.¹³³

Most bowel injuries due to a Veress needle can be managed with a single suture if the injury is recognized immediately. A trocar injury to the bowel requires formal repair. General surgery consultation is prudent. A thermal injury to the bowel may be treated with interrupted sutures if the lesion is not full thickness. However, these patients should be followed post-operatively very carefully and should be observed for a prolonged period of time as energy-based injuries may result in delayed perforation of the bowels. Full thickness bowel injuries should be treated with resection and formal repair.

References

- ¹ Albqami N, Janetschek G. Indications and contraindications for the use of laparoscopic surgery in renal cell carcinoma. *Nature Clin Prac Urol* Jan 2006; 3 (1): 32-37.
- ² Ono Y, Hattori R, et al. Laparoscopic nephrectomy for renal cell carcinoma: the new standard already? *Curr Opin Urol* 2005 Mar; 15 (2):75-78.
- ³ Moon DA, El-Shazly MA, et al. Laparoscopic pyeloplasty: evolution of a new gold standard. *Urology* 2006 Apr; 22: ahead of print.
- ⁴ Bhayani S, Clayman RJ, et al. Surgical treatment of renal neoplasia: evolving towards a laparoscopic standard of care. *Urology* 2003 Nov; 62 (5): 821-826.
- ⁵ Tsuru N, Ushiyama T, Suzuki K. Laparoscopic adrenalectomy for primary and secondary malignant adrenal tumors. *J Endourol* 2005 Jul-Aug; 19 (6): 702-708.
- ⁶ Brunt LM. Minimal access adrenal surgery. *Surg Endosc* 2006 Mar; 20 (3); 351-361.
- ⁷ Guazzoni G, Cestari A, et al. Current role of laparoscopic adrenalectomy. *Eur Urol* 2001 Jul; 40 (1): 8-16.
- ⁸ Jacobs JK, Goldstein RE, Geer RJ. Laparoscopic adrenalectomy: a new standard of care. *Annals of Surg* 1997 May; 225 (5): 495-501.
- ⁹ Vargas HI, Kavoussi LR, et al. Laparoscopic adrenalectomy: a new standard of care. *Urology* 1997 May; 49 (5): 673-678.
- ¹⁰ Tan B, Ost MC, Lee B. Laparoscopic nephroureterectomy with bladder cuff resection: technique and outcomes. *J Endourol* 2005; 19 (6): 664-676.
- ¹¹ Gill IS, Sung GT, et al. Laparoscopic radical nephroureterectomy for upper tract transitional cell carcinoma: the Cleveland Clinic experience. *J Urol* 2000 Nov; 164 (5): 1513-1522.
- ¹² Lindgren BW, Darby EC, et al. Laparoscopic orchiopexy: procedure of choice for the nonpalpable testis? *J Urol* 1998 Jun; 159 (6); 2132-2135.
- ¹³ Samadi AA, Palmer LS, Franco I. Laparoscopic orchiopexy: review of 203 cases with review of diagnosis, operative technique and lessons learned. *J Endourol* 2003 Aug; 17 (6); 365-368.
- ¹⁴ Flasko T, HolmanE, et al. Laparoscopic ureterolithotomy: the method of choice in selected cases. *J Laparoendoscop Adv Surg Tech A* 2005 Apr; 15 (2): 149-152
- ¹⁵ Nambirijan J, Jeschke S, et al. Role of laparoscopy in management of renal stones: single center experience and review of literature. *J Endourol* 2005 Apr; 19 (3): 353-359.
- ¹⁶ Fischer PC, Montgomery JS, et al. 200 consecutive hand-assisted laparoscopic donor nephrectomies: evolution of operative technique and outcomes. *J Urol* 2006 Apr; 175 (4); 1439-1443.
- ¹⁷ Hawasli A, Berri R, et al. Total laparoscopic live donor nephrectomy: a 6 year experience. *Am J Surg* 2006 Mar; 191 (3); 325-329.
- ¹⁸ Smith JA, Herrell SD. Robotic-assisted laparoscopic prostatectomy: Do minimally invasive approaches offer significant advantages? *JCO* 2005 Nov; 23 (32): 8170-8175.
- ¹⁹ Weld KJ, Venkatesh R, et al. Evolution of surgical technique and patient outcomes for laparoscopic partial nephrectomy. *Urology* 2006; 67 (3): 502-506.
- ²⁰ Gill, I. S., S. F. Matin, et al. (2003). "Comparative Analysis of Laparoscopic Versus Open Partial Nephrectomy for Renal Tumors in 200 Patients." *The Journal of Urology* 170(1): 64-68.
- ²¹ Gupta NP, Goel R, et al. Should retroperitoneoscopic nephrectomy be the standard of care for benign nonfunctioning kidneys? An outcome analysis based on 449 cases in a 5 year period. *J Urol* 2004 Oct; 172 (4 Pt 1): 1411-1413.
- ²² Hedican SP. Laparoscopy in Urology. *Surg Clin N Am* 2000 Oct; 80 (5): 1465-1485.
- ²³ Kim JC, Gerber GS. Should laparoscopy be the standard approach used for pelvic lymphadenectomy? *Curr Urol Rep* 2001; Apr; 2 (2): 171-179.
- ²⁴ Reedy MB, Galan HL, et al. Maternal and fetal effects of laparoscopic insufflation in the gravid baboon. *J Am Assoc Gyn Laparosc* 1995 Aug; 2 (4): 399-406.
- ²⁵ Van Basten JP, Knipsheer B, et al. Case retrocar: retroperitoneoscopic tumor nephrectomy during pregnancy. *J Endourol* 2006 Mar; 20 (3): 186-187.
- ²⁶ Kim PT, Kreisman SH, et al. Laparoscopic adrenalectomy for pheochromocytoma in pregnancy. *Can J Surg* 2006; 49 (1): 62-63.

-
- ²⁷ Rolling MD, Chan KJ, Price RR. Laparoscopy for appendicitis and cholecystitis in pregnancy: a new standard of care. *Surg Endosc* 2004 Mar; 18 (2): 237-241.
- ²⁸ Reedy MB, Kallen B, et al. Laparoscopy during pregnancy: a study of 5 fetal health parameters with use of the Swedish Health Registry. *Amer Jour Ob Gynn* 1997; 177: 673-679.
- ²⁹ Anast JW, et al. Difference in outcome for obese patients undergoing laparoscopic radical, partial, or simple nephrectomy. *J Urol* 2004; 172: 2287-2291.
- ³⁰ Kingler HC, et al. Benefits of laparoscopic renal surgery are more pronounced in patients with a high body mass index. *Eur Urol* 2003; 43: 522-527.
- ³¹ Fugita OE, et al. Laparoscopic radical nephrectomy in obese patients: outcomes and technical considerations. *Urology* 2004; 63: 247-252.
- ³² Kapoor et al. Comparison of laparoscopic renal surgery in morbidly obese and non-obese patients. *J Endourol* 2004; 18: 657-660.
- ³³ Sauerland S, Anfrisani L et al. Obesity surgery: evidence based guidelines of the European association of endoscopic surgeons (EAES). *Surg Endosc* 2005 Feb; 19 (2): 200-221.
- ³⁴ Szomstein S, Lo Menzo E, et al. Laparoscopic lysis of adhesions. *World J Surg* 2006 Apr; 30 (4); 535-540.
- ³⁵ Wolf JS, Stoller ML. The physiology of laparoscopy: Basic principles, complications and other considerations. *J Urol* 1994; 152: 294-302.
- ³⁶ P K Harman, I L Kron, H D McLachlan, A E Freedlender, and S P Nolan, Elevated intra-abdominal pressure and renal function, *Ann Surg.* 1982 November; 196(5): 594–597.
- ³⁷ Ost, MC, Beng, JT, Lee, BR, Urological Laparoscopy: Basic Physiological Considerations and Immunological Consequences, *J Urol* 174: 1183 – 1188, 2005
- ³⁸ Rauh R, Hemmerling TM, et al. Influence of pneumoperitoneum and patient positioning on respiratory system compliance. *J Clin Anest* 2001 Aug; 13 (5): 361-5.
- ³⁸ Rauh et al
- ⁴⁰ Chang DT, Kirsh AJ, Sawczuk IS. Oliguria during laparoscopic surgery. *J Endourol* 1994; 8: 349-352.
- ⁴¹ McDougall EM, Monk TG, Wolf JS, et al. The effect of prolonged pneumoperitoneum on renal function in an animal model. *J Am Coll Surg* 1996; 182:317–328.
- ⁴² Bergman S, Nutting A, et al. Elucidating the relationship between cardiac preload and renal perfusion under pneumoperitoneum. *Surg Endosc* 2006 March 16; ahead of print.
- ⁴³ Demyttenaere, S., Feldman, LS., Fried, GM., Effect of Pneumoperitoneum on Renal Perfusion and Function: A systematic Review, *Surg Endosc*, 2007 21: 152-160
- ⁴⁴ Caldwell CB, Ricotta JJ, et al. Changes in visceral blood flow with elevated intra-abdominal pressure. *J Surg Res* 1987; 43: 14-20.
- ⁴⁵ Schoor RT. Regarding laparoscopy-associated mesenteric vascular events: description of an evolving clinical syndrome. *J Laparoendoscop Adv Surg Tech* 1998; 8: 249-250.
- ⁴⁶ Barragan, AB, Frezza, EE, Impact of a warm gas insufflation on operating-room ergonomics during laparoscopic gastric bypass: a pilot study, *Obes Surg.* 2005 Jan;15(1):70-2.
- ⁴⁷ Bishoff, JT, Kavoussi, LR, Laparoscopic Surgery of the kidney, *Campbell's Urology*
- ⁴⁸ Wolf JS, Marcovich R, et al. Survey of neuromuscular injuries to the patient and surgeon during urologic laparoscopic surgery. *Urology* 2000; 55(6): 831-836.
- ⁴⁹ Van Veelen, MA, Kazemier, G., Koopman, J., Goossens, RH, Meijer, DW, Assessment of the Ergonomically Optimal Operating Surface Height for Laparoscopic Surgery, *Journal of Laparoendosc Adv Surg Tech A*, 2002 Feb;12(1):47-52
- ⁵⁰ Florio G, Silvestro C, Polito DS. Peri-umbilical Veress needle pneumoperitoneum: technique and results in 2126 cases. *Chir Ital* 2003 Jan-Feb; 55 (1): 51-54.
- ⁵¹ Bonjer, HJ, Hazebroek, EJ, Kazemier, Gluffrida, MC, Meijer, WS, Lance, JF, Open versus closed establishment of pneumoperitoneum in laparoscopic surgery. *Br J Surg*, 1997, 84: 599-602.
- ⁵² Agresta F., De Simone P. Ciardo, LF. Bedin, N., Direct trocar insertion vs Veress needle in nonobese patients undergoing laparoscopic procedures: a randomized prospective single-center study. *Surg Endosc.* 2004 Dec;18(12):1778-81.

-
- ⁵³ Hasson HM. Open laparoscopy: a retrocar of 150 cases. *J Reprod Med* 1974; 12: 234-238.
- ⁵⁴ Hasson HM. A modified instrument and method for laparoscopy. *Am J Obstet Gynecol* 1971; 110: 886-887.
- ⁵⁵ Phillips PA, Amaral FA. Abdominal access complications in laparoscopic surgery. *J Am Coll Surg* 2001; 192: 525-536.
- ⁵⁶ Brown JA, Canal D, Sundaram CP. Optical-access visual obturator trocar entry into desufflated abdomen during laparoscopy: assessment after 96 cases. *J Endourol* 2005 Sep; 19 (7): 853-855.
- ⁵⁷ Catarci M, Carlini M, et al. Major and minor injuries during the creation of pneumoperitoneum. A multicenter study of 12,919 cases. *Surg Endosc* 2001 Jun; 15 (6): 566-569.
- ⁵⁸ Berquer, R., W. D. Smith, et al. (2002). "An ergonomic study of the optimum operating table height for laparoscopic surgery." *Surgical Endoscopy* V16(3): 416-421.
- ⁵⁹ Berguer, R., D. L. Forkey, et al. (2001). "The effect of laparoscopic instrument working angle on surgeons' upper extremity workload." *Surgical Endoscopy* V15(9): 1027-1029.
- ⁶⁰ Ames C, Frisella AJ, et al. Evaluation of laparoscopic performance with alterations in angle of vision. *J Endourol* 2006 Apr; 20 (4): 281-283.
- ⁶¹ McDougall, E. M., R. V. Clayman, et al. (1994). "Retroperitoneoscopy: The Washington University Medical School experience." *Urology* 43(4): 446-452.
- ⁶² Nakada, S.Y., Moon, T.D., Gist, M. and Mahvi D., Use of the pneumo sleeve as an adjunct in laparoscopic nephrectomy., *Urology* 49 (1997), p. 612
- ⁶³ Patel, VR, Leveillee, RJ, Hand-assisted laparoscopic Nephrectomy for Stage T1 and large T2 renal tumors, *J Endourol*, 2003, Aug;17(6):379-83
- ⁶⁴ Kalra, P., D. T. Glassman, et al. (2006). "Outcomes of hand-assisted laparoscopic nephrectomy in technically challenging cases." *Urology* 67(1): 45-49.
- ⁶⁵ Wolf JS Jr, Moon TD, Nakada SY. Hand assisted laparoscopic nephrectomy: comparison to standard laparoscopic nephrectomy. *J Urol*. 1998 Jul; 160(1): 22-7.
- ⁶⁶ Nadler, R. B., S. Loeb, Clemens, JQ, Batler, RA, Gonzalez, CM, Vardi, IY., "A Prospective Study of Laparoscopic Radical Nephrectomy for T1 Tumors--Is Transperitoneal, Retroperitoneal or Hand Assisted the Best Approach?" *The Journal of Urology* 175(4): 1230-1234.
- ⁶⁷ Baldwin DD, Dunbar JA, Parekh DJ, Wells N, Shuford MD, Cookson MS, Smith JA Jr, Herrell SD, Chang SS, McDougall EM, Single-center comparison of purely laparoscopic, hand-assisted laparoscopic, and open radical nephrectomy in patients at high anesthetic risk. *J Endourol*, Apr;17(3):161-7
- ⁶⁸ Nelson, CP, Wolf JS, Comparison of hand assisted versus standard laparoscopic radical nephrectomy for suspected renal cell carcinoma, *J Urol* 2002 May;167(5):1989-94
- ⁶⁹ Guillonneau B., Vallancien G, Laparoscopic radical prostatectomy: the Montsouris technique *J Urol*. 2000 Jun;163(6):1643-9.
- ⁷⁰ Basillote, JB, Ahlering, TE, Skarecky, DW, Lee DI and Clayman, Laparoscopic radical prostatectomy: review and assessment of an emerging technique. *Surg Endosc*. 2004 Dec;18(12):1694-711
- ⁷¹ Basillote, J. B., Ahlering, T. E., Skarecky, DW., Lee, DI and Clayman, RV, Laparoscopic radical prostatectomy: review and assessment of an emerging technique, *Surg endosc*, 2004, Dec;18(12):1694-1711
- ⁷² Rubenstein JN, Blunt LW, et al. Safety and efficacy of 12mm radially dilating trocar for laparoscopic access. *BJU Int* 2003; 92: 327-329.
- ⁷³ Bishoff JT, Allaf ME, et al. Laparoscopic bowel injuries: incidence and clinical presentation. *J Urol* 1999 Mar; 161 (3): 887-890.
- ⁷⁴ Southern Surgeons Club (1991) A prospective analysis of 1518 laparoscopic cholecystectomies. *New Engl J Med* 324: 1073-1078
- ⁷⁵ Vancaillie, Active electrode monitoring, How to prevent unintentional thermal injury associated with monopolar electrosurgery, at laparoscopy, *Surg Endosc* (1998) 12: 1009-1012
- ⁷⁶ Tarek A. Emam, MB BCH, MCh and Alfred Cuschieri, MD, ChM, FRSE, FRCS, How Safe is High-Power Ultrasonic Dissection?, *Ann Surg*. 2003 February; 237(2): 186-191.
- ⁷⁷ Stefan Schmidbauer, MD, Klaus K. Hallfeldt, MD, Günther Sitzmann, MD, Thorsten Kantelhardt, MD, and Arnold Trupka, MD, Experience With Ultrasound Scissors and Blades (UltraCision) in Open and Laparoscopic Liver Resection, *Ann Surg*. 2002 January; 235(1): 27-30.

- ⁷⁸ Orvieto M, Chien GW, et al. Bipolar electrocoagulation for clipless division of left renal vein branches during laparoscopic living donor nephrectomy. *Transplant Proc* 2004; 36: 2625-2627.
- ⁷⁹ Heniford BT, Matthews BD, Sing RF, Backus C, Pratt B, Greene FL (2001) Initial results with an electrothermal bipolar vessel sealer., *Surg Endosc* 15: 799-801
- ⁸⁰ Kennedy JS, Stranahan PL, et al., High-burst-strength, feedback-controlled bipolar vessel sealing. *Surg Endosc* 1998; 12: 876-878.
- ⁸¹ Landman J, Kerbl K, et al. Evaluation of a vessel sealing system, bipolar electrosurgery, harmonic scalpel titanium clips, endoscopic gastrointestinal anastomosis vascular staples and sutures for arterial and venous ligation in a porcine model. *J Urol* 2003 Feb; 169: 697-700.
- ⁸² Sundaram CP, Rehman J, et al. Hemostatic laparoscopic partial nephrectomy assisted by a water-cooled, high-density, monopolar device without renal vascular control. *Urology* 2003 May; 61 (5); 906-909.
- ⁸³ Urena R, Mendez F, et al. Laparoscopic partial nephrectomy of solid renal masses without hilar clamping using a monopolar radiofrequency device. *J Urol* 2004 Mar; 171 (3); 1054-1056.
- ⁸⁴ Grubb RL 3rd, Sundaram CP, Yan Y, Chen C, McDougall EM, Clayman RV. , Use of titanium staples during upper tract laparoscopic reconstructive surgery: initial experience., *J Urol.* 2002 Oct; 168(4 Pt 1): 1366-9
- ⁸⁵ Hattori R, Yoshino Y, et al. Laparoscopic nephroureterectomy for transitional carcinoma of the renal pelvis and ureter: Nagoya experience. *Urology* 2006 Apr; 67 (4): 701-705.
- ⁸⁶ Shalhav AL, Dunn MD, et al. Laparoscopic nephroureterectomy for upper tract transitional cell carcinoma: The Washington University experience. *J Urol* 2000; 163: 110-1104.
- ⁸⁷ Grubb RL 3rd, Sundaram CP, et al. Use of titanium staples during upper urinary tract laparoscopic reconstructive surgery: initial experience. *J Urol* 2002 Oct; 186 (4 pt 1): 1366-9.
- ⁸⁸ Kapoor, A., C. Nguan, et al. (2006). "Laparoscopic management of advanced renal cell carcinoma with level I renal vein thrombus." *Urology* 68(3): 514-517.
- ⁸⁹ Kerbl K, Chandhoke PS, Clayman RV, et al. Ligation of the renal pedicle during laparoscopic nephrectomy: a comparison of staples, clips and sutures. *J Laparoendoscop Surg* 1993; 3: 9.
- ⁹⁰ Baldwin DD, Desai PJ, et al. Control of the renal artery and vein with the nonabsorbable polymer ligating clip in hand-assisted laparoscopic donor nephrectomy. *Transplantation* 2005 Aug 15; 80 (3): 310-313.
- ⁹¹ Kapoor R, Singh KJ, et al. Hem-o-lok clips for vascular control during laparoscopic partial nephrectomy: a single center experience. *J Endourol* 2006 Mar; 20 (3): 202-204.
- ⁹² Friedman AL, Peters TG, et al. Fatal and nonfatal complications of living kidney donation. *Ann Surg* 2006 Jan; 243 (1): 126-130.
- ⁹³ Bermudez H, Guilloneau B, et al. Initial experience in laparoscopic partial nephrectomy for renal tumor with clamping of renal vessels. *J Endourol* 2003 Aug; 17 (6): 373-378.
- ⁹⁴ Sundaram CP, Rehman J, et al. Hand-assisted laparoscopic radical nephrectomy for renal cell carcinoma with inferior vena cava thrombus. *J Urol* 2002 Jul; 168 (1): 176-179.
- ⁹⁵ Orvieto MA, Chien GW, et al. Simplifying laparoscopic partial nephrectomy: technical considerations for reproducible outcomes. *Urology* 2005; 66 (5): 976-980.
- ⁹⁶ Miller M, Anderson JK, Pearle MS, et al. Resorbable clip migration in the collecting system after laparoscopic partial nephrectomy. *Urology* 2006 Apr; 67 (4); 845.
- ⁹⁷ Ames CD, Perrone JM et al. Comparison of holding strength of suture anchors for hepatic and renal parenchyma. *J Endourol* 2005 Dec; 19 (10): 1221-1225.
- ⁹⁸ Traver MA, Assimios DG., New generation tissue sealants and hemostatic agents: innovative urologic applications. *Rev Urol.* 2006 Summer;8(3):104-11.
- ⁹⁹ Beduschi R, Beduschi MC, Wojno KJ, Jhung M, Williams AL, Wolf JS Jr., Antifibrinolytic Additives to Fibrin Glue for Laparoscopic Wound Closure in Urinary Tract, *J Endourol.* 1999 May;13(4):283-7
- 100 Vanlangendonck R, Venkatesh R, Vulin C, Quayle S, Morrissey K, Landman J., Laparoscopic Ureterocalicostomy: Development of a Technique Simplified by application of Nitinol Clips and a Wet Monopolar Electrosurgery Device, *J Endourol.* 2005 Mar;19(2):225-9
- ¹⁰¹ Tisseel package insert. Baxter Corporation. Glendale, CA.
- ¹⁰² Gill IS, Ramani AP, et al. Improved hemostasis during laparoscopic partial nephrectomy using gelatin matrix thrombin sealant. *Urology* 2005 March; 65 (3): 463-466.
- ¹⁰³ Bernie JE, Hg J, et al. Evaluation of hydrogel tissue sealant in porcine laparoscopic partial nephrectomy model. *J Endourol* 2005 Nov; 19 (9): 1122-1126.

-
- ¹⁰⁴ Bioglue package insert.
- ¹⁰⁵ Hruby G, Marruffo F, Durak E, Collins S, Herron A, Landman J., Comparison of BioGlue reinforced and standard running sutured vesicourethral anastomoses, *Urology*. 2006 Dec;68(6):1355-9
- ¹⁰⁶ Gelfoam package insert.
- ¹⁰⁷ Rehman J, Sundaram CP, et al. Instrumentation for laparoscopic renal surgery – Padron Endoscopic Exposing Retractor (PEER) and Endoholder: point of technique. *Surg Laparosc Endosc Percutan Tech* 2005 Feb; 15 (1): 18-21.
- 108 Prabhu S, Ames CD, Landman J, et al. Comparison of second generation hand-assist devices for surgeon pain and arm circulation. *Urology* 2005; 66: 912-916.
- 109 Weld KJ, Bhayani SB, Belani J, Ames CD, Hruby G, Landman J., Extrarenal vascular anatomy of kidney: assessment of variations and their relevance to partial nephrectomy., *Urology*. 2005 Nov;66(5):985-9
- ¹¹⁰ Venkatesh, R, Landman J, et al. Prevention, Recognition, and management of complications of urologic laparoscopic surgery. *AUA update series* 2003; Volume XXII: lesson 40.
- ¹¹¹ Gomelia LG, Abdel-Meguid KW, et al. Laparoscopic urologic surgery outcome assessment. *J Lap Endoscop & Adv Surg Tech* 1997; 7: 77-86.
- ¹¹² Gill IS, Kavoussi LR, et al. Complications of laparoscopic nephrectomy in 185 patients: A multi-institutional review. *J Urol* 1995; 154: 479-483.
- ¹¹³ Fahlenkemp D, Rassweiler J, et al. Complications of laparoscopic procedures in urology: Experience with 2,407 procedures at 4 German centers. *J Urol* 1999; 162: 765-771.
- ¹¹⁴ Soulie M, Salomon L, et al. Multi-institutional study of complications in 1085 laparoscopic urologic procedures. *J Urol* 2001; 58: 899-903.
- ¹¹⁵ Fuller J, Ashar BS, Carey-Corrado J. Trocar-associated injuries and fatalities: an analysis of 1399 retrocars to the FDA. *J Minim Invasive Gynecol* 2005 Jul-Aug; 12 (4): 302-307.
- ¹¹⁶ Wolf JS, Marcovich R, et al. Survey of neuromuscular injuries to the patient and surgeon during urologic laparoscopic surgery. *Urology* 2000; 55(6): 831-836.
- ¹¹⁷ Romanowski L, Reich H, et al. Brachial plexus neuropathies after advanced laparoscopic surgery. *Fertil Steril* 1993; 60:729-732.
- ¹¹⁸ Simms, M S, Terry, T R, Well leg compartment syndrome after pelvic and perineal surgery in the lithotomy position, *Postgrad Med J* 2005 81: 534-536
- ¹¹⁹ Reisinger KE, Landman J, et al. Laparoscopic renal surgery and the risk of rhabdomyolysis: diagnosis and treatment. *Urology* 2005 Nov; 66 (5 suppl): 29-35.
- ¹²⁰ Roviario GC, Varoli F, et al. Major vascular injuries in laparoscopic surgery. *Surg Endosc* 2002; 16: 1192-1196.
- ¹²¹ Champault G, Cazacu F, et al. Serious trocar incidents in laparoscopic surgery: a French study of 103,852 operations. *Surg Lap Endosc* 1996; 367-370.
- ¹²² Deziel DJ, Millikan WK, et al. Complications of laparoscopic cholecystectomy: a national survey of 4292 hospitals and an analysis of 77,604 cases. *Am J Surg* 1993; 165: 9-14.
- ¹²³ Hashizume H, Sugimachi K. Study group of endoscopic surgery needle and trocar injury during laparoscopic surgery in Japan. *Surg Endosc* 1997; 11: 1198-1201.
- ¹²⁴ Bhoryul S, Vierra MA, et al. Trocar injuries in laparoscopic surgeries. *J Am Coll Surg* 2001; 192: 677-683.
- ¹²⁵ Hanney RM, Carmalt HL, et al. Use of Hasson canula producing major vascular trauma at laparoscopy. *Surg Endosc* 1999; 13: 1238-1240.
- ¹²⁶ Wherry DC, Marohn MR, et al. An external audit of laparoscopic cholecystectomy in the steady state performed in a medical treatment facility of the Department of Defense. *Ann Surg* 1996; 224: 145-154.
- ¹²⁷ Bellamy M. Patients must learn laparoscopy risks. *Aust Doct* 1993; 18: 79.
- ¹²⁸ Lantz PE, Smith JD. Fatal carbon dioxide embolization complicating attempted laparoscopic cholecystectomy. *J Forensic Science* 1994; 39: 1468-1480.
- ¹²⁹ Soderstrom RM. Injuries to major blood vessels during endoscopy. *J Am Assoc Gyn Lap* 1997; 4: 395-398.
- ¹³⁰ Thiel R, Adam JB, et al. Venous dissection injuries during laparoscopic urological surgery. *J Urol* 1996; 155: 1874-1876.
- ¹³¹ Safi KC, Teber D, et al. Laparoscopic repair of external iliac transection during laparoscopic radical prostatectomy. *J Endourol* 2006 Apr; 20 (4): 237-239.

-
- ¹³² Thomas MA, Rha KH, et al. Optical access trocar injuries in urological laparoscopic surgery. *J Urol* 2003 Jul; 170 (1): 61-63.
- ¹³³ Bishoff JT, Allaf ME, et al. Laparoscopic bowel injury: incidence and clinical presentation. *J Urol* 1999; 161: 887-890.
- ¹³⁴ Van der Vort M, Heijnsdijk EAM, Gouma DJ. *Brit J Surg* 2004; 91: 1253-1258.